

Water Lily or Camelotte Sign in Pulmonary Hydatid Cyst – An Orphan Disease

Sudheer T*, Soibampahel M, Mrudula K, Ritisha B, Subodh K and Girish S

Department of Pulmonary Critical Care and Sleep Medicine, All India Institute of Medical Sciences, Rishikesh, India

***Corresponding author:** Sudheer Tale, Department of Pulmonary Critical Care and Sleep Medicine, All India Institute of Medical Sciences, Uttarakhand, India, Email: drtalesudheer@gmail.com

Image Article

Volume 3 Issue 2

Received Date: November 01, 2018

Published Date: November 11, 2018

DOI: 10.23880/cclsj-16000132

Case

A 20 – year – old male without any previous comorbidity presented to pulmonary medicine outpatient department with complaints of dull aching chest pain on right side, dry cough and shortness of breath for the past one year. He was non vegetarian and had no addictions. On general physical examination his vitals were stable and respiratory system examination revealed decreased breath sounds in the right hemithorax. All his routine blood investigations were normal. Chest radiograph revealed homogenous opacity in the right middle and lower zones. Contrast enhanced computed tomography of thorax and abdomen showed a well defined encapsulated cystic lesion of size 12x10x14cm with internal floating membranes (water lily sign or Camelotte sign) with mass effect on adjacent lung parenchyma causing atelectasis and compression of adjacent vessels (Figure 1). Hydatid

serology (IgG) was positive. Patient was treated symptomatically and referred for surgical intervention.

Discussion

Cystic Echinococcosis is a zoonotic disease caused by ingestion of food contaminated with eggs of Echinococcus species. Humans are accidental hosts. Liver is the most common site of involvement followed by lungs. Due to compressible nature of lungs the cysts tend to grow faster in size and rarely calcify [1]. Hydatid cyst consists of three layers the outermost layer is pericyst formed by host tissue, middle layer is ectocyst and innermost is endocyst. Rupture of hydatid cyst occurs in 49% of cases [2]. Rupture of endocyst results in floating membranes within the pericyst mimicking the appearance of water lily hence known as “water lily or Camelotte sign” [3]. Definitive treatment for pulmonary hydatidosis is surgery [4].

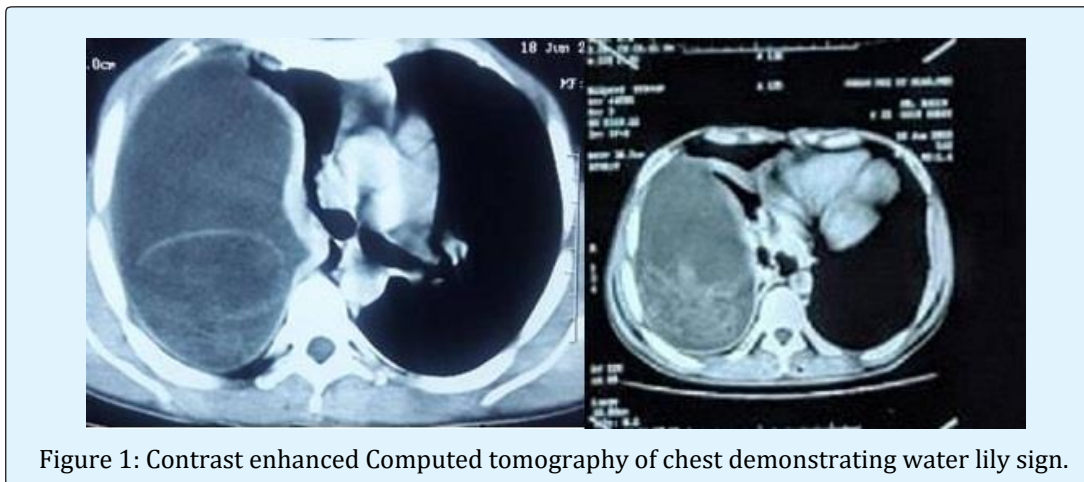


Figure 1: Contrast enhanced Computed tomography of chest demonstrating water lily sign.

References

1. Jerray M, Benzarti M, Garrouche A, Klabi N, Hayouni A (1992) Hydatid disease of the lungs. Study of 386 cases. *Am Rev Respir Dis* 146(1): 185-189.
2. Garg MK, Sharma M, Gulati A, Gorski U, Aggarwal A, et al. (2016) Imaging in pulmonary hydatid cysts. *World J Radiol* 8(6): 581-587.
3. Von Sinner WN (1991) New diagnostic signs in hydatid disease; radiography, ultrasound, CT and MRI correlated to pathology. *Eur J Radiol* 12(2): 150-159.
4. Sarkar M, Pathania R, Jhobta A, Thakur BR, Chopra R (2016) Cystic pulmonary hydatidosis. *Lung India* 33: 179-191.

