

Clinical Radiology & Imaging Journal

ISSN: 2640-2343

Assessment of Normal Portal Vein Diameter and Velocity using Ultrasound

Maram Mohammed Fathi Ahmed

Author's Details

Inaya Medical College, Saudi Arabia,

Tel: 00966557863865;

Email: maramfathi1991@gmail.com

Volume 3 Issue 2

Received Date: February 14, 2019

Published Date: March 28, 2019

Published by



MEDWIN PUBLISHERS

Committed to Create Value for Researchers

Dedication

I dedicate this research to my mother for her kindness and devotion, and for her endless support.

I also dedicate this work to my husband, who has been my eternal rock Thanks for always being there for me.

I dedicate this research also to my teachers who taught me to think, and express and my supervisor, Dr. Elsir Ali.

Finally this is for my sisters, brother, friend, doctors, and any person being by my side.

Acknowledgement

I would like to express my deepest gratitude to my advisor, Dr. El sir Ali, for his excellent guidance, caring, patience and providing me with an excellent atmosphere for doing research. I would like to thank Dr. Mohammed Alfadel, who let me experience the research of freshwater mussels in the field and practical issues beyond the textbooks, patiently corrected my writing and financially supported my research. I would also like to thank Dr. Selah and Dr. Ahmed Abd ALraheem, for guiding my research for the past several months and helping me to develop my background in physics, Doppler, and practical. A special thanks goes to my husband, Ashraf, who was willing to participate in my final touches at the last moment.

ث حبل ا ص خ لم

، ة يتوصل الى قوف تاجومل ربيع ديرولا ة عرسو يبابل ديرولل يعي بظلا رطلل ري ياعم عضول ة ساردلا هذه تي رج ديرولا رطلل ني ب طبرلل رشؤم لكشت اهن امك . يبابل ديرولا طغض عافترا نع ركبملا فشكلا يف اهنم دافتس وي . نطبل ا طيحمو لوظلاو نزولاو سنجلاو رمعلا ساسا يل ع مسجلا صاوخ عم نين ادوسلا دن ع هت عرسو يعي بظلا

قركبم قل حرم يف يبابل ديرولا يف مدلا طغض عافترا صي خشت يف دعاستس اهنأ يف نمكت ة ساردلا ة يمها ص حفا تقوو قفلكت نم للقت فوس كلذ نع الضف ؛ اتافعا ضلما بن جتل

تيرجأ . ة يعامتجال تاساردلل اهتئبع تو يئاصح ليلحتل اجم انرب ة طساوب اهل يلحتو و . تاناي بلا عم ج مت (نم) هرتفلا يف موطرخا ة يالو يف يرحب موطرخا لىفش تسم يف ة جودملا ة يتوصل الى قوف تاجوملل هروص ة ئام ي ضرمل (نطبلل هيعي بط ص حفا ة جيتن تنانكو (يثنأ 51 و اركذ 49) ضيرم 100 يل ع (2015 ريبم سيدى و يام تائى فلما نم مه قنمزملا دبكل ا ضارم نم نوناعي نى ذل ا ي ضرمل او يركسل ا ضرم ، مدلا طغض عافترا نم نوناعي نى ذل ا م ج نم (3%) تل كس دق ف قن س (20-29) نيب حوارتت ة يرمعلا تائى فلما مظعم نأ ج ئائى نل ليلحت دجوو (ه دعبتس مل ا و ، (39%) قن س نب مس (160-169) نم لوظلاو ، (3%) نول شم يو مارج و لى ك (60-69) نم حوارتت نازوالا مظعمو . قن ي عل ا مدقتل عم يبابل ديرولا رطلل قدايز تنانك هساردلا ج ئائى ن . ي ضرمل نم (30%) يف مس (70-79) نيب ام نطبل ا طيحم هت عرسو يبابل ديرولل يعي بظلا رطلل يف رثؤي ال (يثنأ / ركذ) ي ضرمل سنج نكلو نزولاو رمعلا يف

طابترا نع فشكلا مت . ينطبل ا هطيحمو ي ضرمل لوظو يبابل ديرولا رطلل نيب ريبك طابترا ي ن ع فشكلا متي مل ديرولا رطلل صقانت عم ديرولا ل خاد مدلا ة عرس قدايز) ديرولا ل خاد مدلا ة عرسو يبابل ديرولا رطلل نيب ة ي اغلل ريبك نيب ققال ع كان ه نأ اضي ا ساردلا تدجوو . ققبا سلا تاساردلا ج ئائى ن عم يشامتتو هعقو تم تنانك هجيتنل ا . (يبابل ا هيلماعل تاسا ي قلال او نين ادوسلا يدل يبابل ديرولا ة عرسو رطل

دبكل ا م ج عم هتقالعو هت عرسو يبابل ديرولا رطلل سايق قسارد قوررضب ة ساردلا تصوأو

Table of Contents

Abstract	1
Chapter I	2
Introduction	2
Problem of the Study	
Objectives	
General Objective: The general objective of this study is to assess normal portal vein diameter and its velocity using ultrasound.	
Specific Objectives	
Importance of the Study	
Overview of the Study	
Chapter II	3
Theoretical Background	3
Portal Vein Anatomy	
Portal Vein Physiology	
Portal Vein Pathology	
Previous Studies	
Chapter III	7
Methodology	7
Data Presentation	
Chapter IV	8
Results	8
Frequency Distribution	
Relationships	
Chapter V	11
Discussion, Conclusion and Recommendations	11
Discussion	
Conclusion	
Recommendations	
References	11

Abstract

This study was conducted to establish standards of normal portal vein diameter and portal venous velocity via ultrasound and can be helpful in early detection of portal hypertension as well as to have indigenous index for healthy Sudanese correlate with body characteristic based on age, gender, weight, height and abdominal circumference (AC). Importance of this study is to help in diagnosis portal hypertension in early stage to avoid the complication as well as to reduce the cost and time of examination. The data was collected, analyzed by using Statistical Packaged for Social Studies (SPSS). Duplex ultrasound examinations were performed in Khartoum Bahri Hospital, Khartoum State during the period) from May 2015 to December 2015(, on 100 patients (49 male and 51 female) with normal abdominal scan (hypertension, DM and patient who has chronic liver disease are exclusion criteria). The analysis of the results found that the most age group ranged between 20 to 29 years forming (33%) of the sample volume, the most body weight ranged from (60 to 69) Kg forming (38%), the height of the body from (160 to 169) cm in (39%), the abdominal circumference between (70-79) cm in (30%) of patients. In result we found the portal vein diameter increase with age and weight but the values are similar in male and female. No significant correlation was detected between portal vein diameter, height and abdominal circumference (AC). Highly significant correlation was detected between portal vein diameter and portal vein velocity of patient (increase velocity with decreasing diameter), these was expected and goes with previous study. The study also found that there was significant correlation between Sudanese portal vein diameter and velocity and international standard. The study recommended further study to correlate normal portal vein diameter and velocity with liver size.

Abbreviations: US: Ultrasound; PV: Portal vein; HA: Hepatic Artery AC: Abdominal Circumference; SPSS: Statistical Package for Social Sciences; TIPS: Trans Jugular Intrahepatic Portosystemic Shunt; HVPG: Hepatic Venous Pressure Gradient; ANOVA: Analysis of Variance; NS: No Significant difference; *: Significant difference; **: Highly Significant difference.

Chapter I

Introduction

The portal vein is a vessel that moves blood from the spleen and gastrointestinal tract to the liver's capillary beds. It is about three to four inches in length and is usually formed by the convergence of the superior mesenteric and splenic veins behind the upper edge of the head of pancreas. In some individuals, the inferior mesenteric vein may enter this junction instead. The portal vein supplies approximately 75 percent of hepatic blood flow. The portal vein is not a true vein in that it does not drain into the heart. Instead, its functions are to supply metabolic substrates to the liver and to maintain that ingested substances are first processed by the liver before entering normal circulation [1].

When the portal venous pressure exceeds 10 mm Hg Portal hypertension occurs. The consequences of portal hypertension are similar. The commonest cause of portal hypertension is Liver cirrhosis. Sonography plays a major role in the assessment of portal hypertension Because of its availability, lack of ionizing radiation and rapid assessment. Even if the additional use of Doppler modalities improves the assessment of patients suspected of having portal hypertension, gray scale assessment of portal vein diameter is important in the initial evaluation. Knowing the normal portal venous dimension in a specified population is so crucial [2]. Portal hypertension is a commonly consider clinical condition with multiple causes and several sequel. Ultrasound is an accurate and safe in assessing its cause, severity and complications. The ultrasonic features that help identify its etiology will be discussed as will the criteria that allow an assessment of disease severity and its complications [1].

Problem of the Study

The normal portal vein diameter and portal venous velocity have variable measurement in grayscale and Doppler ultrasound standard where use to compare it to normal, this standard come from Europe standard might not suit the Sudan's measurement, also measurement might follow body characteristic (age, weight, height, abdominal circumference) and gender, there for finding the normal Sudanese measurement in respect body characteristic will

provide dynamic standard.

Objectives

General Objective: The general objective of this study is to assess normal portal vein diameter and its velocity using ultrasound.

Specific Objectives

- a. To measure portal vein diameter.
- b. To measure portal vein velocity and direction.
- c. To find the characteristic of normal portal vein waveform.
- d. To correlate the portal vein diameter with velocity.
- e. To correlate the body characteristic with portal vein diameter and velocity.

Importance of the Study

This study will helps in diagnosis portal hypertension in early stage to avoid the complication. As well as it will reduce the cost and time of examination.

Overview of the Study

This study is concerned with normal portal vein diameter sonographically by using grayscale and Doppler. It falls into five chapters.

- a. Chapter one is an introduction, which include introductory notes about the study explaining the word shown in the title, as well as statement of the problem answer the question why do I do this study, and study objectives which include the general objective and specific objectives and importance of the study.
- b. While chapter two is include a theoretical background (anatomy, physiology, pathology) and comprehensive scholarly literature reviews concerning the previous studies of problem.
- c. Chapter three deals with the methodology, where it provides an outline of material and methods used to acquire the data in this study as well as the method of analysis approach.
- d. While the results were presented in chapter four.
- e. Chapter five include discussion of results, conclusions and recommendations followed by references and appendices.

Chapter II

Theoretical Background

Portal Vein Anatomy

The blood vessel that conducts blood from the gastrointestinal tract and spleen to the liver is hepatic portal vein. This blood is filling with nutrients that have been taken from food, and the liver filters drugs and toxins that may have been interred with the food. 75% of total liver blood flow is through the hepatic portal vein, with the remainder coming from the hepatic artery proper. The blood leaves the liver to the heart in the hepatic veins [3]. The hepatic portal vein is not a true vein, because it conducts blood to capillary beds in the liver and not directly to the heart. It is a major component of the hepatic portal system, one of only two portal venous systems in the body – with the hypophyseal portal system being the other [3]. The hepatic portal vein is usually formed by the confluence of the superior mesenteric and splenic veins and also receives blood from the inferior mesenteric, gastric, and cystic veins [3]. Elevated blood pressure in the hepatic portal vein is an example of condition that involving the portal vein causes illness and death. This condition, called portal hypertension, is a major complication of cirrhosis [3].

Tributaries of the Hepatic Portal Vein

- a. Splenic vein
- b. Superior mesenteric vein
- c. Inferior mesenteric vein
- d. Gastric veins
- e. Cystic vein

Measuring approximately 8 cm (3 inches) in adults, the hepatic portal vein is located in the right upper quadrant of the abdomen, originating behind the neck of the pancreas [3]. In most of people, the hepatic portal vein is come from the union of the superior mesenteric vein and the splenic vein [4]. So the hepatic portal vein is occasionally called the splenic-mesenteric confluence [3]. Sometimes, the hepatic portal vein also directly communicates with the inferior mesenteric vein, although this is highly variable. Other tributaries of the hepatic portal vein include the cystic and gastric veins [3]. The portal vein divides into right and left immediately before reaching the liver. It branches further, forming portal venules. Each portal venule courses beside a hepatic arteriole and form the portal triad. These vessels ultimately empty into the hepatic sinusoids to supply blood to the liver [3].

Portacaval Anastomoses

There are different anastomoses of the portal venous system with the systemic venous system. In cases of portal hypertension these anastomosis may become engorged, dilated, or varicosed and subsequently rupture [3].

Accessory Hepatic Portal Veins

Accessory hepatic portal veins are those veins that drain directly into the liver without joining the hepatic portal vein. These include the paraumbilical veins as well as veins of the lesser omentum, falciform ligament, and those draining the gallbladder wall (Figure 1) [3].

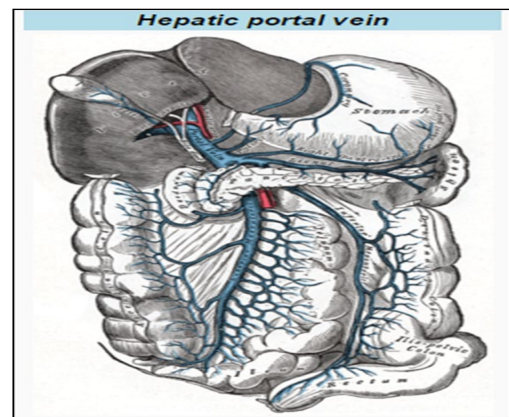


Figure 1: The portal vein and its tributaries. It is formed by superior mesenteric vein, inferior mesenteric vein, and splenic vein [3].

The hepatic portal vein is a vessel that moves blood from the spleen and gastrointestinal tract to the liver. It is approximately three to four inches in length and is usually formed by the merging of the superior mesenteric and splenic veins behind the upper edge of the head of the pancreas. In some individuals, the inferior mesenteric vein may enter this intersection instead [4].

In most people, the portal vein splits into left and right veins before entering the liver. The right vein then branches off into anterior and superior veins [5]. The portal vein supplies approximately 75 percent of blood flow to the liver. The portal vein is not a true vein, which means it does not drain into the heart. Instead, it brings nutrient-rich blood to the liver from the gastrointestinal tract and spleen. Once there, the liver can process the nutrients from the blood and filter out any toxic substances it contains before the blood

goes back into general circulation [5]. Abnormally high blood pressure in the portal vein is known as portal hypertension. The condition may cause the growth of new blood vessels that bypass the liver, which can result in the circulation of unfiltered blood throughout the body. Portal hypertension is one of the potential serious complications of liver cirrhosis, which is a condition where normal liver tissue is replaced with scar tissue [5]. The main vessel in the portal venous system is Portal vein (PV) and IT drains blood to the liver from the gastrointestinal tract and spleen [5].

Gross Anatomy

The portal vein, usually measures about 8 cm in adults. It originates behind the neck of the pancreas and is classically formed by the confluence of the superior mesenteric and splenic veins, and also receives blood from the inferior mesenteric, gastric, and cystic veins [6]. Immediately before reaching the liver, the portal vein divides into left portal vein (supplying liver segments II, III, IV) and the right portal vein, which subsequently divides further into anterior (supplying liver segments V and VIII) and posterior (supplying liver segments VI and VII) portal veins [6]. Each portal venule courses alongside a hepatic arteriole and the two vessels forming the vascular components of the portal triad. These vessels ultimately empty into the hepatic sinusoids to supply blood to the liver [6]. 75% of the blood supplied to the liver comes from the portal vein, but it only supplies 50% of the oxygen supply to the liver [6].

Variant Anatomy

The variation incidence of portal vein is reported to be about ~25% (range 20-30%), so prior to procedures such as liver transplantation, complex hepatectomy and portal vein embolization it should be recognized [6].

- a. Portal vein trifurcation (most common).
- b. Divide the Portal vein into three branches: right anterior portal vein, right posterior portal vein, and left portal vein.
- c. Right posterior portal vein divides as the first branch of the portal vein; the right anterior and the left portal veins are originating from a common trunk.

There is an increased risk of bile duct hilar anatomical variation in the presence of portal vein variants [6].

Portal Vein Physiology

The liver's dual blood supply consists of the hepatic portal vein and hepatic arteries. Approximately 75% of hepatic blood flow is derived from the hepatic portal vein, while the remainder is from the hepatic arteries [7]. The hepatic portal vein does not drain the blood into the heart as most veins, rather, it is delivers venous blood into another capillary system, namely the hepatic sinusoids of the liver.

The hepatic portal vein doing two tasks in drain venous blood from the gastrointestinal tract to the liver, it supplies the liver with metabolic substances and it ensures that substances ingested are first filtered by the liver before reaching the systemic circulation. So that the possible toxins that may be ingested can be detoxified in liver before they are released into the systemic circulation. Second, the liver is the first organ to absorb nutrients just taken in by the intestines [7].

After draining into the liver sinusoids, blood from the liver is drained by the hepatic vein [7]. Substances absorbed in the small intestine go first to the liver for filtration before continuing to the heart. Not all of the gastrointestinal tracts are part of this system. The system starts from the lower portion of the esophagus to the upper part of the anal canal. It also includes venous drainage from the spleen and pancreas [8]. Many drugs are substantially filtered by the liver before reaching general circulation. This is known as the first pass effect. As a result, certain drugs can only be taken via certain routes. For example, nitroglycerin can be taken under the tongue or transdermal (through the skin) and thus is absorbed in a way that bypasses the portal venous system but cannot be swallowed because the liver would inactivate the medication. Inversely, dextromethorphan, a cough suppressor, is best taken orally because it needs to be metabolized by the liver into dextrorphan in order to be effective. This latter principle is that of most prodrugs. The use of suppository is a way to by-pass partially the portal vein: the upper 1/3 of the rectum is drained into the portal vein while the lower 2/3 is drained into the internal iliac vein that goes directly in the inferior vena cava (thus by-passing the liver) [8].

Blood flow to the liver is unique in that it receives both oxygenated and (partially) deoxygenated blood. As a result, the partial gas pressure of oxygen (pO₂) and perfusion pressure of portal blood are lower than in other organs of the body. Blood passes from branches of the portal vein through cavities between "plates" of hepatocytes called sinusoids. Blood also flows from branches of the hepatic artery and mixes in the sinusoids to supply the hepatocytes with oxygen. This mixture percolates through the sinusoids and collects in a central vein which drains into the hepatic vein. The hepatic vein subsequently drains into the inferior vena cava. The hepatic artery provides 30 to 40% of the oxygen to the liver, while only accounting for 25% of the total liver blood flow. The rest comes from the partially deoxygenated blood from the portal vein [8]. Interestingly, the liver at rest consumes about 20% of the total body oxygen. Because that the total liver blood flow is very high, at about 1 up to two liters a minute [8].

Parts of the Portal Venous System are the:

- a. Hepatic portal vein
- b. Splenic vein

- c. Superior mesenteric vein
- d. Inferior mesenteric vein

The superior mesenteric vein and the splenic vein join to form the hepatic portal vein. The inferior mesenteric vein connects in the most of people on the splenic vein, but in some people, it is connect on the portal vein or the superior mesenteric vein [8]. Roughly, the portal venous system corresponds to areas supplied by the celiac trunk, the superior mesenteric artery, and the inferior mesenteric artery [8] (Figure 2).

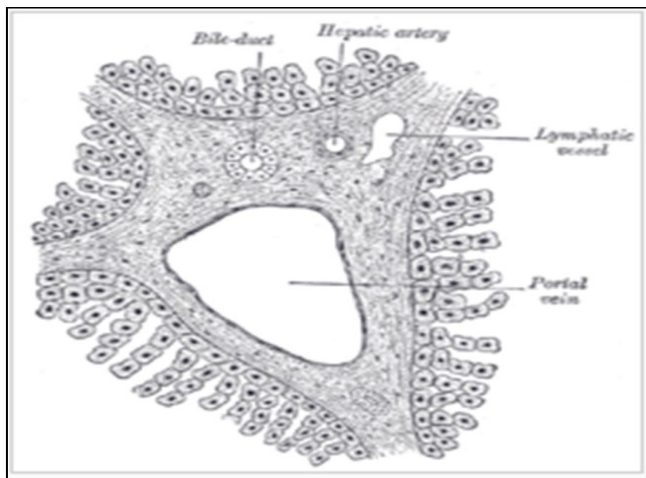


Figure 2: Microscopic section through a small portal vein branch inside the liver [8].

Portal Vein Pathology

Portal Hypertension

Portal hypertension is increase the blood pressure in the portal vein system, which is including the portal vein, and its branches and tributaries. Portal hypertension is known as raising or elevation of hepatic venous pressure more than 5mmHg. Generally, in clinical practice the pressure is not measured directly until the decision to place a Transjugular intrahepatic portosystemic shunt (TIPS) has already been made. As part of that procedure, a hepatic vein wedge pressure is measured with the assumption of no pressure drop across the liver yielding portal vein pressure [9].

Signs and Symptoms

Outcome of portal hypertension are caused by blood being forced down alternate channels by the elevate resistance to flow by the systemic venous system quite than the portal system [9]. They include:

- a. Ascites (free fluid in the peritoneal cavity).
- b. Hepatic encephalopathy.
- c. Increased risk of spontaneous bacterial peritonitis.

- d. Increased risk of hepatorenal syndrome.
- e. Splenomegaly (enlargement of the spleen) with a consequent accumulation of red blood cells, white blood cells, and platelets, together leading to mild pancytopenia.
- f. Spread of varices like esophageal varices, gastric, varices, anorectal varices (not to be confused with hemorrhoids), and caput medusae. Esophageal and gastric varices pose an ongoing risk of life-threatening bleeding, with bloody vomiting or melena [9].

Causes can be Classifying as Pre-Hepatic, Intra-Hepatic, and Post-Hepatic.

- a. Prehepatic causes either portal vein thrombosis or congenital atresia.
- b. Intrahepatic causes include liver cirrhosis, hepatic fibrosis (e.g. due to Wilson's disease, hemochromatosis, or congenital fibrosis), and less commonly noncirrhotic causes such as schistosomiasis, massive fatty change and diffuse granulomatous diseases (e.g. sarcoidosis, miliary tuberculosis) [9].
- c. Posthepatic obstruction occurs at any level between liver and right heart, including hepatic vein thrombosis, inferior vena cava thrombosis, inferior vena cava congenital malformation, and constrictive pericarditis [9].
- d. The gold standard for assessing the severity of portal hypertension is HVPG (hepatic venous pressure gradient) measurement, and replaced the old one - contrast angiography. Portal hypertension is defined as HVPG greater than or equal to 5mm Hg and is considered to be clinically significant when HVPG exceeds 10 to 12 mm Hg [9]).

Treatment

- a. Portosystemic shunts
- b. Prevention of bleeding [10]

Portal Vein Thrombosis

Cauchois–Eppinger–Frugoni syndrome is used previously in a form of venous thrombosis affecting the hepatic portal vein, which can lead to portal hypertension and decreasing in the blood supply to the liver [11].

Signs and Symptoms

Fever, symptoms of indigestion and gradually worsening abdominal pain can cause by Portal vein thrombosis. However, it can also develop a symptomatic, leading to portal hypertension before it is diagnosed [11]. Other symptoms can develop based on the cause. For example, liver cirrhosis if develop portal vein thrombosis, bleeding or other signs of liver disease may be present. If portal vein thrombosis develops from Pyle phlebitis, signs of infection such as fever, chills, night sweats may be present. Causes can include pancreatitis,

cirrhosis, diverticulitis, and cholangiocarcinoma. It is also a known complication of splenectomy. The diagnosis of portal vein thrombosis is usually made by ultrasound, computed tomography with contrast or magnetic resonance imaging. D-dimer levels in the blood may be elevated as a result of fibrin degradation [11]. Treatments include anticoagulants, shunts, bypass surgery, and transplants [11].

Previous Studies

Assessment of Normal Doppler Parameters of Portal Vein and Hepatic Artery in 37 Healthy Iranian Volunteers: Hadi Rokni Yazdi 2006 Tehran, Iran [12].

Doppler sonography is a valuable safe method for detection of different liver diseases. However, there is rare information on normal measurement of hepatic artery (HA) and portal vein (PV) in Iran. This study was conducted to estimate normal Doppler indices of HA and PV in normal Iranian population. In this cross-sectional study, 37 (18 females, 19 male) healthy volunteers aged from 20 to 40 years did Doppler sonography after 8 hours of Nall by mouth. PV was measured at crossing point with inferior vena cava in normal respiration and HA in the hilum of liver. The mean \pm SD PV diameter was 9.36 ± 1.65 mm. The mean \pm SD maximum, and mean velocity of PV were 35.28 ± 16.54 and 27.317 ± 13.139 , respectively. The mean \pm SD peak systolic velocity and resistance index of HA were 67.64 ± 33.48 and 0.76 ± 0.07 , respectively. In the result show the normal Doppler measurement of HA and PV depend on different factors like gender, respiratory phase and technique of measurement and there is no uniform standard technique for these measurements. These factors must be considered when using Doppler parameters for diagnosis of liver disease [12].

Portal Vein Measurement by Real Time Sonography

Jeffrey Weinreb, Sheila Kumari, Gail Phillips, Rubem Pochaczewsky 1982 American Roentgen Ray Society [13]. Ultrasound produces a simple and reliable definition of the portal veins. A standard normal portal vein measurement is presented. The mean diameter of the portal vein in 107 patients aged from 21 to 40 years was 11 ± 2 mm. This information can be useful in assess portal hypertension in a variety of clinical situations. Sonography has been found to be a valuable modality for diagnosing abnormalities of the portal venous system. With the development of sonography, assessing of the portal venous system has become very simple and reliable. While the medical literature abounds with descriptions of normal and abnormal sonographic portal venous anatomy, little attention has been focused on actual diameter of the portal vein. This information may be particularly important in detecting and evaluating patients with portal hypertension. To obtain this data, we

sonographically measured the portal veins in a large series of normal patients [13].

Sonographic Evaluation of Normal Portal Vein Diameter in Nigerians

Anakwue A C, Uloma Nwogu, 2009, Nigeria [14]

Portal vein diameter is a diagnostic index helpful in measuring portal hypertension which is present in many disease conditions including cirrhosis where it occurs in more than 60% of cases. The objective of this work is to determine the normal portal vein diameter in adult Nigerians. In this work we used a 2D ultrasound- a non- invasive method to measure the portal vein diameter in 200 adults aged from 20 to 79 years of both genders. Results were the mean diameter of normal portal vein in the subjects was $11.45 \text{mm} \pm 1.49$. Conclusion of this study was the portal vein diameter obtained in this work is comparable to that found in Caucasians. This information can be useful in diagnosing and treating portal hypertension in a variety of clinical situations [14].

Impact of Anthropometrical Parameters on Portal Vein Diameter and Liver Size in a Subset of Karachi Based Population

Tanya Raza Siddiqui, Nuzhat Hassan, Pashmina Gul, 2014, Karachi. [15]

The purpose of this study was to assess the impact of anthropometrical measurement on portal vein diameter and liver size by ultrasound in a subset of Karachi population.

There are 459 healthy subjects were included in this cross sectional study. After measuring weight and height of each subject, Portal vein diameter and both liver lobes were measured by gray scale ultrasonography. Students T test and ANOVA were applied for statistical analyses.

Results was with increasing age, portal vein diameter and right lobe of liver increased significantly (p value < 0.001). Increase in portal vein diameter was also observed with increasing in body mass index (0.8 cm in underweight - 1.1 cm in obese subjects). Right and left liver lobes size also increased with increase in body mass index (p value < 0.001 and 0.001). Gender did not have any effect on portal vein diameter and liver size.

Conclusion of study was Age and body mass index are credible parameters to consider for avoiding rule out hepatomegaly and portal hypertension. Knowing the right and left liver measurements also assist a clinician in selecting a donor for liver transplantation.

Keywords: Anthropometrical measurements; Liver; Portal vein diameter

Chapter III

Methodology

Materials used to collect the Data (Tools): Ultrasound machines with frequencies transducer 3.5 to 5 MHz, with Doppler capability. Coupling jells and TV card with 16 bit to capture the ultrasound image using the personal computer.

Study Design: This is an analytical, cross-sectional study where the patient selected randomly, free from disease.

Study Population: The study includes adult patients referred to Khartoum North Hospital for abdominal ultrasound for all ages, gender and ethnic groups.

Exclusion criteria

- Diabetic patient, hypertensive patient.
- Patient who has chronic liver disease.

Sampling: The sample of this study is a convenience sample where only those units which are accessible at the time are taken. Sample size 100 patients selected randomly.

Area and Duration of study: This study was conducted in Khartoum North Hospital in Khartoum State. Khartoum is a capital of the Republic of Sudan located at the confluence of the White Nile flowing north from Lake Victoria and the Blue Nile flowing west from Ethiopia. In duration from May 2015 to December 2015.

Method of Data collection(Technique)

Sonographic Technique: The PV examined with a real time curve array transducer having a focal zone (3 to 5 cm). Most patients can be adequately imaged with 3.5 to 5 MHz frequencies. Optimum color and power Doppler capabilities when evaluates vessels or vascularity of a structure should instruct the patients to take deep inspirations to fully visualize (Figure 3).

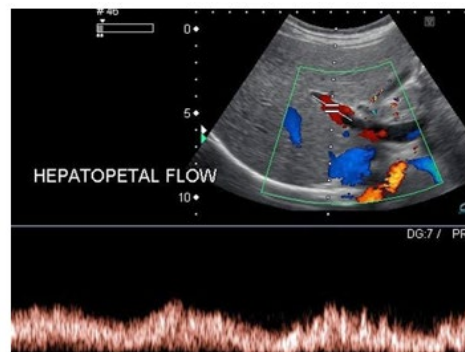


Figure 3: Duplex image of portal vein.

The Portal Vein normally should have forward flow into the liver which called (hepatopetal flow). As seen in this image, the color is red, which is set for movement towards the probe. Carefully look at the color box on the side of the image to know the setting. If there is flow reversal, which called hepatofugal (tip: Fugitive= run away) and represents portal hypertension [16].

Variables of Study: The data will be collected using the following variables: PV diameter and flow direction .PV velocity, age, gender and ethnic abdominal circumference (AC).

Method of Data Analysis: Data was analyzed by using Statistical Packaged for Social Studies (SPSS) and Excel under windows. The variable included in the study was portrayed using histogram plots with normal distribution curve over-

plotted. As well the association between the PV diameter (independent variable) and the others variables (dependent) was investigated using multiple linear regression stepwise analysis and logistic regression. The selected variable was used to classify the normal PV diameter and velocity (using K-means and Fisher discriminant analysis) [17].

Data Presentation

Data presented by tables, figures, and diagrams.

Ethical Consideration: The researcher preserves all special data of the population of study and all the data written in data collecting sheets by their agreement no individual subject information should be out this study.

Chapter IV

Results

Frequency Distribution

As shown in Table 1 & Figure 4, 9 out of 100 (9%) of patients understudy their age less than 20 years, followed by 33 out of 100 (33%) between 20-29 years, 25 out of 100 (25%) between 30-39 years, 22 out of 100 (22%) between 40-49 years and the rest 11 out of 100 (11%) their age 50 years or above. Classification of patients according to gender was illustrated in Table 2 & Figure 5. 49 out of 100 (49%) were males and 51 out of 100 (51%) were females. Table 3 & Figure 6 shows classification of patients according to weight. 8 out of 100 of patients under investigation their weight below 50 kilograms, followed by 22 ranged between 50-59 kilograms, 38 out of 100 (38%) ranged between 60-69 kilograms, 25 out of 100 (25%) ranged between 70-79 kilograms and 7 out of 100 (7%) weighed 80 kilograms or above.

Height of interviewed patients was demonstrated in Table 4 & Figure 7. 9 out of 100 (9%) their height below 150 cm, 26 out of 100 (26%) ranged between 150-159 cm, 39 out of 100 (39%) ranged between 160-1169 cm and 26 out of 100 (26%) their height 170 cm or above. Classification of patients according to abdominal circumference was shown in Table 5 & Figure 8. 14 out of 100 (14%) their AC below 60 cm, followed by 27 out of 100 (27%) between 60-69 cm, 30 out of 100 (30%) between 70-79 cm, 18 out of 100 (18%) between 80-89 cm and the rest 11 out of 100 (11%) their AC 90 cm or above.

Portal vein diameter of patients understudy was presented in Table 6 & Figure 9. 13 out of 100 (13%) their portal vein diameter [18] less than 8 mm, 29 out of 100 (29%) ranged between 9-10 mm, 33 out of 100 (33%) between 11-13 mm and 25 out of 100 (25%) were 13 mm or above. Table 7 & Figure 10 show classification of patients according to portal vein velocity [19]. 3 out of 100 (3%) their portal vein velocity less than 30 cm/sec, 31 out of 100 (31%) between 30-34 cm/sec, 30 out of 100 (30%) between 35-39 cm/sec, 24 out of 100 (24%) between 40-44 cm and the rest 12 out of 100 (12%) their portal vein velocity 45 cm/sec or above. All cases their portal vein direction was heptaopetal (Table 8) [20].

Relationships

Correlation between portal vein diameter and selected parameters of the study was shown in Table 9. Significant correlation ($r=0.234$; $P=0.019$ and $r=0.22$; $P=0.028$) was

found between portal vein diameter and age and weight of patients, respectively. No significant correlation ($r=-0.055$; $P=0.59$ and $r=0.177$; $P=0.247$) was detected between portal vein diameter and height and abdominal circumference of patients, respectively. While highly significant correlation ($r=-0.628$; $P=0.0$) was noticed between portal vein diameter and portal vein velocity of patients under investigation.

Means \pm standard deviations were 11.16 ± 1.70 mm, 33.83 ± 11.91 years, 1.51 ± 0.50 , 63.86 ± 10.68 kilograms, 161.40 ± 8.75 cm, 72.89 ± 11.68 cm and 38.58 ± 5.83 cm/sec for portal vein diameter, age, gender, weight, height, abdominal circumference and portal vein velocity respectively of interviewed patients.

Part I: Frequency distribution

Age (years)	Frequency	%
<20	9	9
20-29	33	33
30-39	25	25
40-49	22	22
≥ 50	11	11
Total	100	100%

Table 1: Classification of patients according to age.

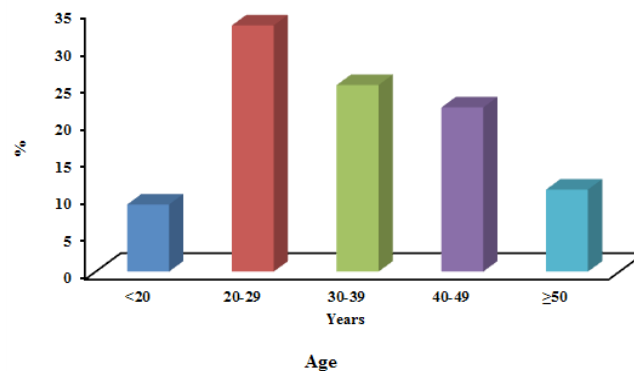


Figure 4: Classification of patients according to age.

Gender	Frequency	%
Males	49	49
Females	51	51
Total	100	100%

Table 2: Classification of patients according to gender.

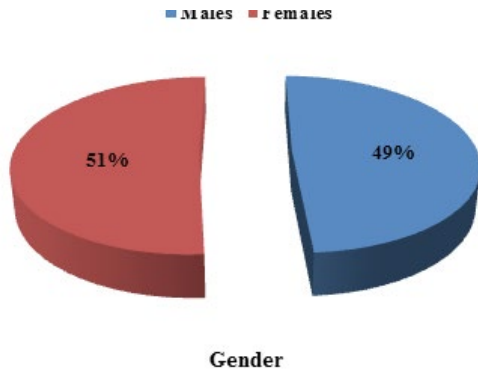


Figure 5: Classification of patients according to gender.

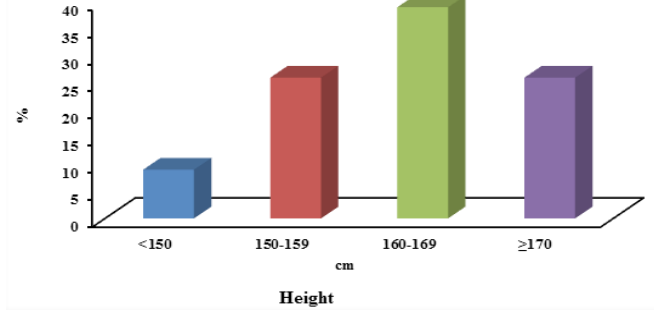


Figure 7: Classification of patients according to height.

Weight (kg)	Frequency	%
<50	8	8
50-59	22	22
60-69	38	38
70-79	25	25
≥80	7	7
Total	100	100%

Table 3: Classification of patients according to weight.

AC (cm)	Frequency	%
<60	14	14
60-69	27	27
70-79	30	30
80-89	18	18
≥90	11	11
Total	100	100%

Table 5: Classification of patients according to AC.

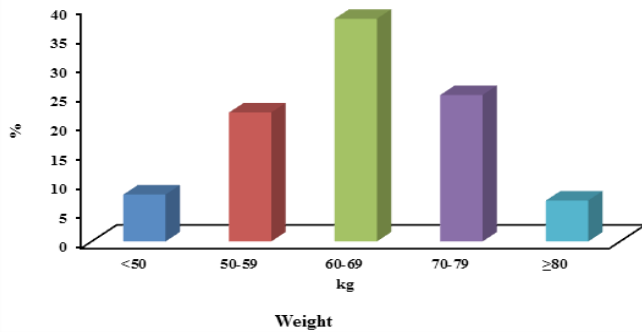


Figure 6: Classification of patients according to weight.

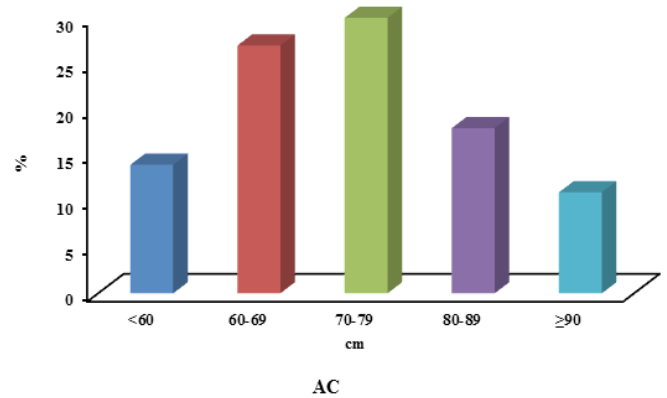


Figure 8: Classification of patients according to AC.

Height (cm)	Frequency	%
<150	9	9
150-159	26	26
160-169	39	39
≥170	26	26
Total	100	100%

Table 4: Classification of patients according to height.

Portal vein diameter (mm)	Frequency	%
<8	13	13
09-Oct	29	29
Nov-13	33	33
≥13	25	25
Total	100	100%

Table 6: Classification of patients according to portal vein diameter.

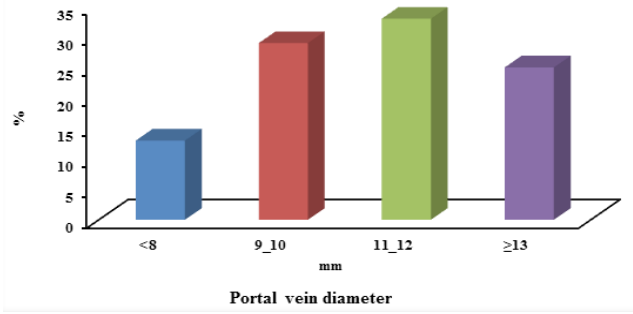


Figure 9: Classification of patients according to portal vein diameter.

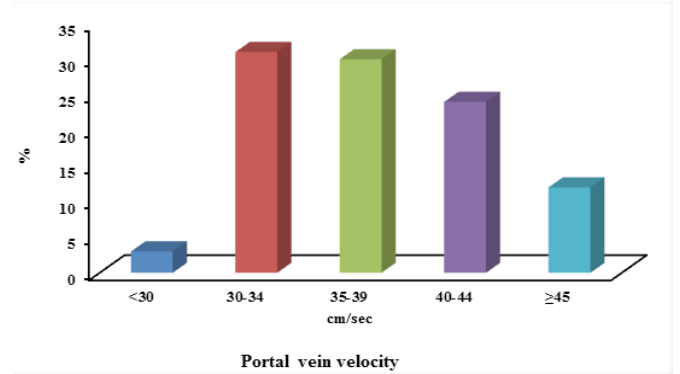


Figure 10: Classification of patients according to portal vein velocity.

Portal vein velocity (cm/sec)	Frequency	%
<30	3	3
30-34	31	31
35-39	30	30
40-44	24	24
≥45	12	12
Total	100	100%

Table 7: Classification of patients according to portal vein velocity.

Portal vein direction	Frequency	%
Heptaopetal	100	100
Total	100	100%

Table 8: Classification of patients according to portal vein direction.

Part II: Relationships

Parameter	Mean±SD	r	P-value
Portal vein diameter (mm)	11.16±1.70		
Age (years)	33.83±11.91	0.234	0.019*
Gender	1.51±0.50	-0.055	0.59N.S
Weight (kg)	63.86±10.68	0.22	0.028*
Height (cm)	161.40±8.75	0.177	0.247N.S
AC (cm)	72.89±11.68	0.08	0.43N.S
Portal vein velocity (cm/sec)	38.58±5.83	-0.628	0.0**

Table 9: Correlation between portal vein diameter and selected parameters of the study.

Chapter V

Discussion, Conclusion and Recommendations

Discussion

This is cross section descriptive study deal with assessment of normal portal vein diameter and velocity using ultrasound taking 100 subjects. Several previous studies in various setting has support ultrasound scanning as non-invasive, cost effected, reliable, and accurate tool for measuring portal vein diameter and velocity. Under this study the researcher analyzed 100 patients, out of them (51%) were females and (49%) were males, the most common age group 20-29 years (33%) followed by 30-39 years (25%) mean \pm SD of age (33.83 \pm 11.91). Correlation between portal vein diameter and selected parameters of the study was shown in Table 9.

- Significant correlation ($r=0.234$; $P=0.019$ and $r=0.22$; $P=0.028$) was found between portal vein diameter and age and weight of patient, respectively.
- No significant correlation ($r= -0.055$; $P= 0.59$ and $r=0.177$; $P=0.247$) was detected between portal vein diameter and height and AC of patient, respectively.
- While highly significant correlation ($r=-0.628$; $P=0.0$) was noticed between portal vein diameter and portal vein velocity of patient under investigation.

Means \pm standard deviation were 11.16 \pm 1.70 mm, 33.83 \pm 11.91 years, 1.51 \pm 0.50, 63.86 \pm 10.68 kilograms, 161.40 \pm 8.75 cm, 72.89 \pm 11.68 cm and 38.58 \pm 5.83 cm/sec for portal vein diameter, age, gender, weight, height, abdominal circumference , and portal vein velocity respectively of interviewed patients.

This finding was supported by Jeffrey Weinreb [13] and his group studied and also supported by Anakwue AMC [14], Uloma Nwogu in 2009, whom they found that was significant relation between portal vein diameter and velocity. The results were also supported by Tanya Raza Siddiqui and his group they found that was significant relation between age and portal vein diameter. However it was different from the finding of [12] Rokni Yazdi H in summer 2006, whom they found that the mean \pm SD PV diameter was 9.36 \pm 1.65 mm, the mean \pm SD portal vein velocity was 35.28 \pm 16.54, which smaller than our result, that may be due to differences in techniques used and the sample studied [21-23]. Another source of variance in the results found may be due to difference in the age of participants .Result was expected and

goes with previous study [24,25].

Conclusion

This study is concerned with normal portal vein diameter by using grayscale and Doppler ultrasound. The study gives indigenou index for Sudanese normal portal vein diameter and velocity correlate with body characteristic. Ultrasound scanning is noninvasive, informative, and cost effective tools measuring portal vein and its velocity .there is significance relation between Sudanese portal vein diameter and velocity and stander one. There were significant correlation was found between portal vein diameter and age and weight of patient, respectively, increase diameter when these parameter increase. No significant correlation was detected between portal vein diameter and height and abdominal circumference of patient, respectively. While highly significant correlation was noticed between portal vein diameter and portal vein velocity of patient under investigation. The result was expected and goes with previous study.

Recommendations

- Measurement of portal vein diameter and velocity is important in ultrasound examination in order to early detecting of portal hypertension.
- Duplex Ultrasound can be helpful in early detection of portal hypertension as well as to have indigenou index for correlate that with body characteristic.
- Sonographer should be well trained in taking measurement accurately.
- Taking into account the patient preparation before ultrasound get correct measurements.
- Observance the important of body characteristic that affect in measurement.
- Further studies are recommended to correlate normal portal vein diameter and velocity with liver size by using large sampling for accurate result.

References

- Bolondi L, Gandolfi L, Arienti V, Caletti GC, Corcioni E, et al. (1982) Ultrasonography in the diagnosis of portal hypertension: Diminished response of portal vessels to respiration. *Radiology* 142(1): 167-172.
- Vilgrain V, Lebrec D, Menu Y, Scherrer A, Nahum H (1990) Comparison between ultrasonographic signs and the

- degree of portal hypertension in patients with cirrhosis. *Gastrointest Radiol* 15(1): 218-222.
3. Lafortune M, Marleau D, Breton G, Viallet A, Lavoie P, et al. (1984) Portal venous system measurements in portal hypertension. *Radiology* 151(1): 27-30.
 4. Bolondi L, Mazziotti A, Arienti V, Casanova P, Gasbarrini G, et al. (1984) Ultrasonographic study of portal venous system in portal hypertension and after portosystemic shunt operations. *Surgery* 95(3): 261-269.
 5. Ralls PW (1990) Color Doppler sonography of the hepatic artery and portal venous system. *AJR Am J Roentgenol* 155(3): 517-525.
 6. Moriyasu F, Nishida O, Ban N, Nakamura T, Sakai M, et al. (1986) "Congestion index" of the portal vein. *AJR Am J Roentgenol* 146(4): 735-739.
 7. Haag K, Rössle M, Ochs A, Huber M, Siegerstetter V, et al. (1999) Correlation of duplex sonography findings and portal pressure in 375 patients with portal hypertension. *AJR Am J Roentgenol* 172(3): 631-635.
 8. Platt JF, Rubin JM, Ellis JH (1995) Hepatic artery resistance changes in portal vein thrombosis. *Radiology* 196(1): 95-98.
 9. Kok T, van der Jagt EJ, Haagsma EB, Bijleveld CM, Jansen PL, et al. (1999) The value of Doppler ultrasound in cirrhosis and portal hypertension. *Scand J Gastroenterol Suppl* 230: 82-88.
 10. Zoli M, Dondi C, Marchesini G, Cordiani MR, Melli A, et al. (1985) Splanchnic vein measurements in patients with liver cirrhosis: A case-control study. *J Ultrasound Med* 4(12): 641-646.
 11. Portal vein.
 12. Yazdi HR, Sotoudeh H (2006) Assessment of Normal Doppler Parameters of Portal Vein and Hepatic Artery in 37 Healthy Iranian Volunteers. *Iranian J Radiol* 3(4): 213-216.
 13. Weinreb J, Kumari S, Phillips G, Pochaczewsky R (1982) Portal vein Measurements by Real Time Sonography. *American Roentgen Ray Society* 139: 497-499.
 14. Anakwue AMC, Anakwue R, Agwu KK, Idigo F (2009) Sonographic Evaluation of Normal Portal Vein Diameter in Nigerians. *European J Scien Resear* 36(1): 114.
 15. Siddiqui TR, Hassan N, Gul P (2014) Impact of anthropometrical parameters on portal vein diameter and liver size in a subset of Karachi based population. *Pak J Med Sci* 30(2): 384-388.
 16. Rossi, Plinio, Ricci, P, Broglia L (2000) Portal Hypertension. *Diagnostic Imaging and Imaging-Guided Therapy*, Springer, pp: 51.
 17. Hawaz Y, Admassie D, Kebede T (2012) Ultrasound Assessment of Normal Portal Vein Diameter in Ethiopians Done at Tikur Anbessa Specialized Hospital. *East Cent Afr J surg* 17(1): 90-93.
 18. Weerakkody Y, Jones J, Portal vein. Radiopedia.
 19. Portal vein. Wikipedia.
 20. Hepatic portal system. Wikipedia
 21. Portal hypertension. Wikipedia
 22. Kumar V, Abbas A, Aster J (2012) Robbins Basic Pathology. 9th (Edn.), Elsevier/Saunders, pp: 608.
 23. Krebs C, Odwin C, Fleischer A (2004) Appleton & Lange review for the ultrasonography examination. 3rd (Edn.), McGraw Hill Professional.
 24. Strous RD, Edelman MC (2007) Eponyms and the Nazi era: time to remember and time for change. *Isr Med Assoc J* 9(3): 207-214.
 25. Ultrasound Of The Liver-Normal. Ultrasoundpaedia.

