

“Unreported Nuclear Medicine Findings in Congenital Emangiomas Involving Lower Limb (Klippel-Trenaunay Syndrome)”

Rashid R^{1*}, Zohaib B², Ali I², Ambrene Y², Syed Ali RN³ and Jawad G¹

¹Institute of nuclear medicine oncology and radiotherapy (INOR), Pakistan

²Governemnt degree college, Pakistan

³Government college University, Pakistan

Case Report

Volume 1 Issue 2

Received Date: June 09, 2016

Published Date: July 01, 2016

DOI: 10.23880/doi-16000108

***Corresponding author:** Rashid Rasheed, Institute of nuclear medicine oncology and radiotherapy (INOR), KP, Abbottabad, Pakistan, Email: dr.nmd.paec@gmail.com

Hemangioma is a prevalent problem among the vascular abnormalities and is the very common benign tumor of infancy and childhood. It is characterized by rapid growth of endothelial cells that commonly arises in the head and neck region (60%), followed in frequency by the trunk (25%) and extremities (15%) [1]. Two types of congenital hemangiomas exist including rapidly involuting congenital hemangiomas and noninvoluting congenital hemangiomas [2].

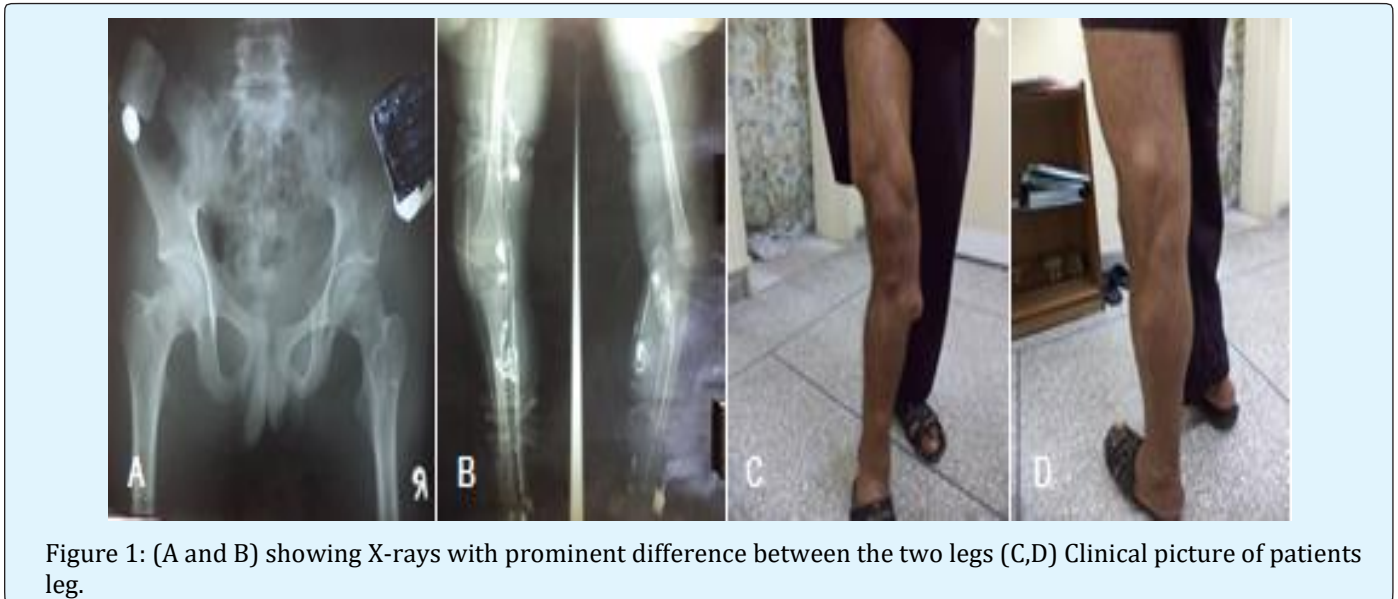
Klippel-Trenaunay syndrome (KTS) is a rare, sporadic capillary venolymphatic malformation (CVLM) with limb overgrowth [3-5]. The exact cause of KTS is unknown. Various theories were proposed to explain the syndrome but none of them clearly depicted the scenario [6]. Most commonly it appeared to be associated with paradominant multiallelic aetiology [7]. KTS presentation differs widely from truncular to extratruncular and from infiltrating to limited forms, mainly containing three vascular elements including veins, capillaries and lymphatics [3, 8]. It encompasses a dermal capillary stain linked with venous varicosities. These veins have deformed with no valves usually. The involvement of lower limb is prominent along with perineum or abdomen, while the upper limb, trunk or neck are less commonly involved [5]. KTS should be differentiated from Parkes-Weber syndrome which is a mixed, high-perfusion, high shunt arteriovenous abnormality but the clinical features, management and prognosis of these two syndromes are different [9]. Apart from physical symptoms of thrombosis, cellulitis, pruritus, ulcers, skin

discomfort and pain, KTS is also associated with social and emotional dysfunction [10]. So KTS requires a detailed multidisciplinary disease management approach for improved patient care by optimizing the treatment given to the patient [10][11]. Doppler ultrasound is the first imaging technique used in the differentiating vascular tumors from other vascular abnormalities [12-14]. Doppler study with ultrasonography and MRI are the most common non-invasive diagnostic imaging techniques used in hemangioma [15]. We are presenting a case of this syndrome with unreported nuclear medicine findings.

Case Presentation

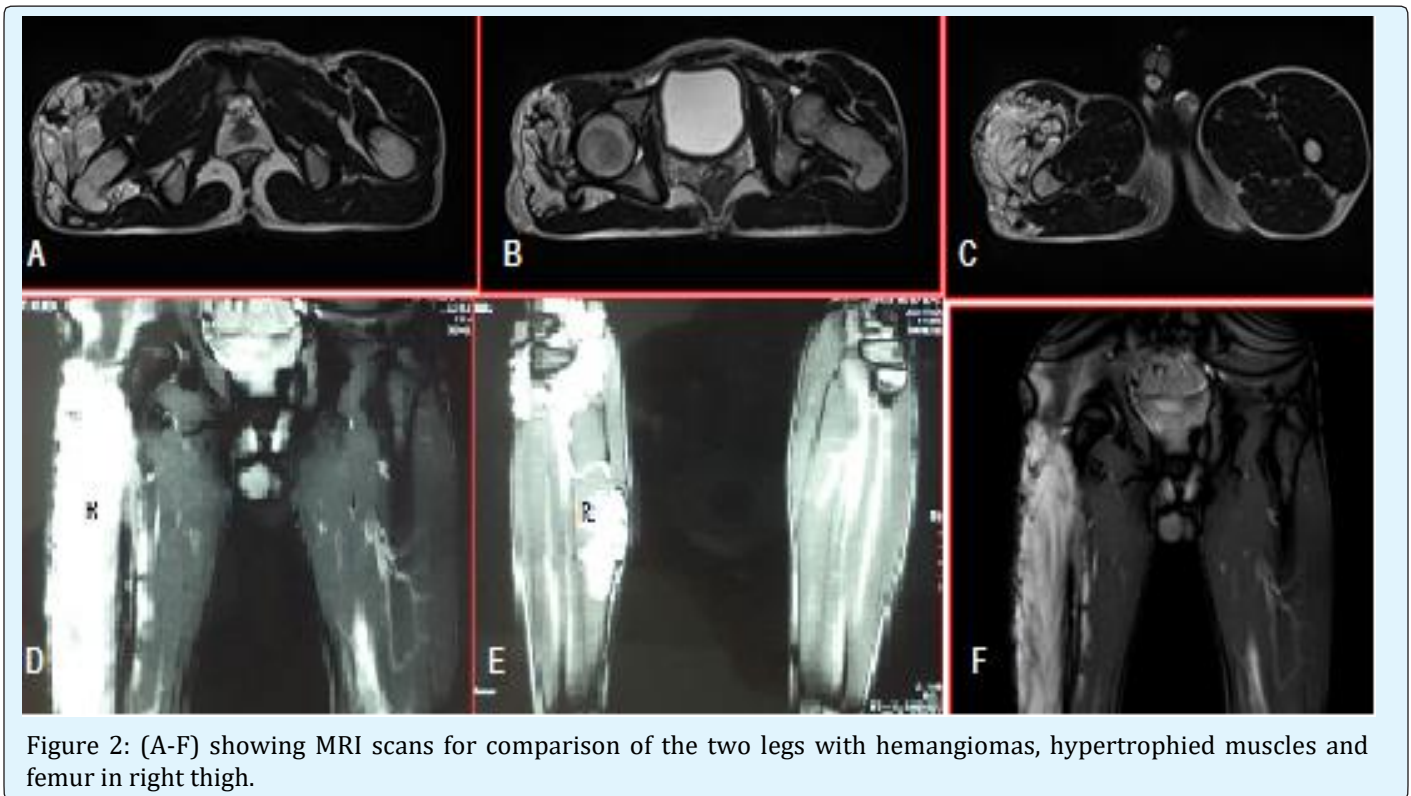
A 17 years young male presented to hospital with multiple swelling, pain and discoloration all over the right leg since childhood (figure1: c, d). Pain and swelling increase with standing and walking. Cutaneous pigmentation was obvious throughout the limb. The patient visited surgeon and he advised him to undergo the Doppler ultrasound of right leg. On the basis of the results, vascular abnormality was noted and varicose veins were ruled out. Spider like hemangioma was found on clinical examination. All the baseline investigations of the patient including Complete Blood Count (CBC), Differential Leukocyte Count (DLC), Liver Function Tests (LFTs) and Renal Function Tests (RFTs) were normal. X ray of pelvis and both femora showed that hip bone and right femur of involved side are larger than the contralateral side (Figure1: A). This discrepancy is also evident on

angiography which showed hypertrophied and slightly large right femur when compared to left femur (Figure 1 B).



MRI of the patient showed prominent muscles and bone hypertrophy of right thigh muscles and femur.

Cutaneous vascular hemangiomas are prominent as well as in (figure 2).



Radionuclide venography was done with tourniquet method to check the patency of deep vein valves. Injection was given simultaneously in both legs and flow of tracer was evaluated off and on tourniquet technique as given in the guidelines (Figure 3). RNV showed patent valves and no flow was seen from deep to superficial veins which help to rule out possibility of varicose veins. Patient was managed conservatively and surgical procedure due to suspicion of varicose veins was ruled out. Leg discrepancy was solved with thick sole shoe. Cutaneous dilatations were managed with compression stockings. Patient was reassured regarding disease. Medical management was done for symptoms like pain and itching.

determine the disease prognosis [18]. MRI of the patient was done that showed that the patient has hemangiomas in the right leg, appearing white as compared to remaining part of the image.

Scintigraphy may be utilized to assess regional blood flow, patency of valves and bone vascularity in KTS [12]. When vein stripping, sclerosis, or ligation, or sclerosis are essential radionuclide venography or contrast venography is done to depict perforators, collaterals, and deep connections of the extremities [19,20]. Various techniques were developed for better visualization of the deep veins, including retrograde venography, ascending venography, with pericalcaneal, femoral, and peritrochanteric injection of contrast material [21]. Scintivenography of the patient was done that showed increased blood flow and bone vascularity in the right limb of patient along with patent deep valves.

KTS disease varies greatly from patient to patient, so every patient needs different treatment on the basis of his or her clinical presentation. For better management of the patient and to achieve the aim of improving patient's quality of life, a multidisciplinary disease management approach is essential to be followed [12,22,23].

Patients of KTS should be treated conservatively, with special emphasis on symptomatic relief. Patients with functional limbs and having little or no edema, ulceration, bleeding, or pain are usually managed conservatively [12,24]. Elastic compression stockings, elevation of the affected limb or intermittent pneumatic compression pumps are extensively used in managing patients with varicose veins, edema and swelling of the extremities [4,12]. Compression stockings are highly recommended for all KTS patients, especially when they start walking [12,23]. Patients with cellulitis or thrombophlebitis should be managed with antibiotics, analgesics, and elevation [24]. Corticosteroids should be used when appropriate. Antibiotics are recommended only in the case of infections [12,25]. Proper skin care and regular cleansing should be done in patients with minor KTS to prevent the development of severe disabling conditions [12,23].

Our patient was being considered for surgical procedure for varicose veins in a peripheral setup but with proper investigations it became obvious that KTS is genetic disorder that involves no improvement in patient's quality of life after surgery. As the disease has no permanent cure so no surgery was advised. Over the counter analgesic and anti-inflammatory products were recommended to treat pain and inflammation. The use of elastic compression stockings and elevation of the right leg were emphasized for treating the varicose veins. Some

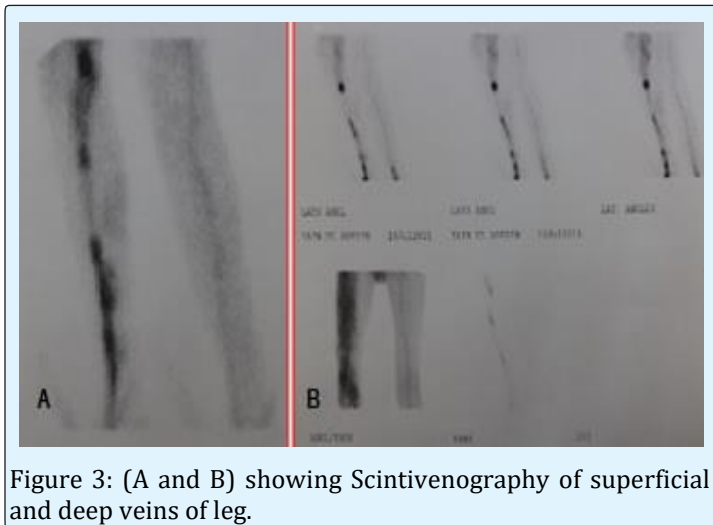


Figure 3: (A and B) showing Scintivenography of superficial and deep veins of leg.

Discussion

The patient presented with haemangioma of the lower limb and was evaluated with three basic diagnostic tests to check the extent and severity of the issue and appropriate designing of the therapy. In the management of hemangiomas, plain X-rays of the long bones (scanograms) are most helpful to see bone related abnormalities [3]. Lower limb X-Rays of the patient were taken that clearly showed hypertrophy of the right limb that appeared as a white mass as compared to the remaining image.

Magnetic resonance imaging (MRI) helps in accurate visualization of patient's soft tissues. Hypertrophy of muscle and bone, presence of dilated veins and arteries, and pelvic and abdominal vascular abnormality can be assessed with MRI [12,16]. It is also helpful in differentiating bone, fat, muscle hypertrophy and lymphedema of muscle, fat and bone [3]. MRI is useful in visualizing the extent of lesions along with infiltration of deep body tissues before treatment [13,14,17]. In this way, MRI helps in designing therapy for the patient, monitoring patient's response to therapy, and to

life style modifications like the use of heel inserts was promoted that help the patient during walking or standing. It was repeatedly emphasized that the patient should routinely clean the affected area to prevent the growth of microbes. Patient was advised for routine follow ups as it can help in accurate and timely management of patient in the case of any infection or other complexities.

Conclusion

The patient presented to hospital was having Klippel Trenaunay Syndrome with varicose veins. Because of the genetic origin of KTS, no surgery was performed and the patient was recommended to use analgesics and follow other life style modifications for improvement of his quality of life. Therefore in the management of suspected KTS it may be suggested that clinical examination should follow with x-rays and if still found ambiguous either MRI or Scintigram may be of help to rule out KTS.

References

- Mulliken J B (1988) Diagnosis and natural history of hemangiomas.
- Krol A, CJ MacArthur (2005) Congenital hemangiomas: rapidly involuting and noninvoluting congenital hemangiomas. *Archives of facial plastic surgery* 7(5): 307-311.
- Gloviczki P, and D Driscoll (2007) Klippel-Trenaunay syndrome: current management. *Phlebology* 22(6): 291-298.
- Jacob AG, Anila G Jacob, David J Driscoll, William J. Shaughnessy, Anthony W Stanson, Ricky P Clay, et al. (1998) Klippel-Trenaunay syndrome: spectrum and management. in *Mayo Clinic Proceedings*, Elsevier 73(1): 28-36.
- Cohen MM (2000) Klippel-Trenaunay syndrome. *American journal of medical genetics* 93(3): 171-175.
- Tian X, M Liu, R Kadaba (2004) Positional cloning of a novel angiogenic factor gene: VG5Q mutations cause susceptibility to KTS. *Nature* 427(1): 640-645.
- Oduber C E, C M van der Horst, R C Hennekam (2008) Klippel-Trenaunay syndrome: diagnostic criteria and hypothesis on etiology. *Annals of plastic surgery* 60(2): 217-223.
- Zea M I, Mohammad Hanif, Mohammad Habib, Ahmed Ansari et al. (2009) Klippel-Trenaunay Syndrome: a case report with brief review of literature. *Journal of dermatological case reports* 3(4): 56-59.
- Weber F P (1906) Angioma-formation in connection with hypertrophy of limbs and hemi-hypertrophy.
- Breugem C C, Merkus MP, Smitt JH, Legemate DA, van der Horst CM, et al. (2004) Quality of life in patients with vascular malformations of the lower extremity. *British journal of plastic surgery* 57(8): 754-763.
- Hannawi S, I Salmi (2013) Klippel Trenaunay Syndrome, Inverse Klippel Trenaunay Syndrome: Hypertrophy of Lower Limbs and Atrophy of the Upper Limbs and Facial Muscles: Case Report and Literature Review. *J Clin Exp Dermatol Res.* 4(172): 2.
- Kihiczak G G, Meine JG, Schwartz RA, Janniger CK (2006) Klippel-Trenaunay syndrome: a multisystem disorder possibly resulting from a pathogenic gene for vascular and tissue overgrowth. *International journal of dermatology* 45(8): 883-890.
- Dubois J, Laurent Garel, Andrée Grignon, Michèle David, Louise Laberge, et al. (1998) Imaging of hemangiomas and vascular malformations in children. *Academic radiology* 5(5): 390-400.
- Dubois J, L Garel (1999) Imaging and therapeutic approach of hemangiomas and vascular malformations in the pediatric age group. *Pediatric radiology* 29(12): 879-893.
- Enjolras O (1997) Classification and management of the various superficial vascular anomalies: hemangiomas and vascular malformations. *The Journal of dermatology* 24(11): 701-710.
- Howlett D C, Roebuck DJ, Frazer CK, Ayers B (1994) The use of ultrasound in the venous assessment of lower limb Klippel-Trenaunay syndrome. *European journal of radiology* 18(3): 224-226.
- Kern, S, Niemeyer C, Darge K, Merz C, Laubenberger J, Uhl M (2000) Differentiation of vascular birthmarks by MR imaging: An investigation of hemangiomas, venous and lymphatic malformations. *Acta Radiologica* 41(5): 453-457.
- Laor T, P Burrows (1998) Congenital anomalies and vascular birthmarks of the lower extremities.

- Magnetic resonance imaging clinics of North America 6(3): 497-519.
19. Phillips GN, Gordon DH, Martin EC, Haller JO, Casarella W (1978) The Klippel-Trenaunay Syndrome: Clinical and Radiological Aspect 1. Radiology 128(2): 429-434.
 20. Burrows P E, Tal Laor, Harriet Paltiel, Richard L Robertson (1998) Diagnostic imaging in the evaluation of vascular birthmarks. Dermatologic clinics 16(3): 455-488.
 21. Thoma M L, G Macfie (1974) Phlebography in the Klippel-Trenaunay syndrome. Acta Radiologica Diagnosis (Sweden) 15(1): 43-56.
 22. Noel A A, Gloviczki P, Cherry KJ, Rooke TW, Stanson AW, Driscoll DJ (2000) Surgical treatment of venous malformations in Klippel-Trenaunay syndrome. Journal of vascular surgery 32(5): 840-847.
 23. Enjolras O, J B Mulliken (1993) The current management of vascular birthmarks. Pediatric dermatology 10(4): 311-333.
 24. Meine J, R Schwartz, C Janniger (1997) Klippel-Trenaunay-Weber syndrome. Cutis 60(3): 127-132.
 25. Viljoen D, N Saxe, J Pearnj, P Beighton (1987) The cutaneous manifestations of the Klippel-Trenaunay-Weber syndrome. Clinical and experimental dermatology 12(1): 12-17.

