



## Ropy and Wiry-Fibroma-Thecoma Testis

**Bajaj A\***

Consultant Histopathology, AB Diagnostics, India

**\*Corresponding author:** Anubha Bajaj, Consultant Histopathology, A. B.diagnostics, A-1, Ring Road Rajouri Garden, New Delhi, 110027, India, Tel: 00911141446785; Email: anubha.bajaj@gmail.com

**Mini Review**

**Volume 8 Issue 1**

**Received Date:** January 10, 2024

**Published Date:** February 29, 2024

**DOI:** [10.23880/hij-16000236](https://doi.org/10.23880/hij-16000236)

### Abstract

Fibrothecoma of testis emerges as an exceptionally discerned, sex cord stromal tumour comprised of spindle shaped, ovoid or spherical cells intermingled with quantifiably variable collagen. Sertoli cell or granulosa cell components are absent although minimal aggregates of diverse sex cord cells may be discerned. Mitotic activity is minimal  $\leq 5$  mitoses per 10 high power fields although up to 10 mitoses per 10 high power fields may be encountered. Generally, focal haemorrhage and necrosis are absent. Cellular density and stromal collagen is variable. Additionally designated as the cofibroma, testicular fibroma or neoplasm of thecoma/fibroma group, testicular fibrothecoma commonly incriminates testis or paratestis.

**Keywords:** Fibrothecoma; Chromosome; Neoplasam; Heterozygosity; Haemorrhage

**Abbreviations:** SF1: Steroidogenic Factor 1; SMA: Smooth Muscle Actin; UICC: Union for International Cancer Control; HMB45: Human Melanoma Black 45; BHCG: Beta Human Chorionic Gonadotropin; AFP: Alpha Fetoprotein; LDH: Lactate Dehydrogenase.

### Introduction

Testicular fibrothecoma commonly emerges within 16 years to 69 years with mean age of disease discernment at 44 years. Generally, neoplasm occurs within third decade or fourth decade [1,2]. Of obscure aetiology and pathogenesis, testicular fibrothecoma may be associated with specific conditions as Gorlin's syndrome or nevoid basal cell carcinoma syndrome. Besides, anomalies within PTCH gene may be encountered.

Testicular neoplasms may exceptionally exhibit loss of heterozygosity within chromosome 9q22.3 which is a genetic locus for PTCH gene [2,3].

Genes implicated within genesis of testicular carcinoma are expounded as

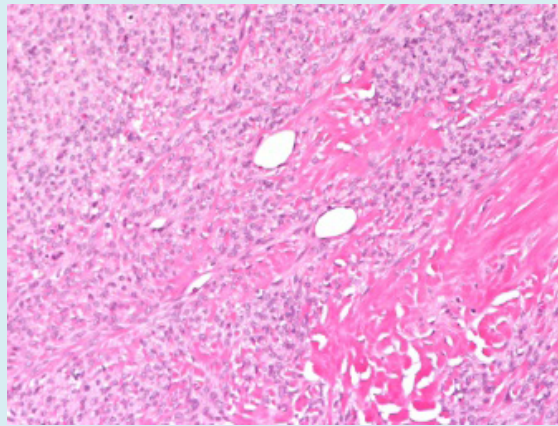
- UCK1: chromosome 1
- HPGDS: chromosome 4
- CENPE: chromosome 4
- TERT: chromosome 5
- TERT/CLPTM1L: chromosome 5
- SPRY4: chromosome 5
- BAK-1: chromosome 6
- MAD1L1: chromosome 7
- DMRT1: chromosome 9
- AFT7IP: chromosome 12

- KITLG: chromosome 12
- RFWD3: chromosome 16
- TEX14: chromosome 17
- PPM1E: chromosome 17 [2,3].

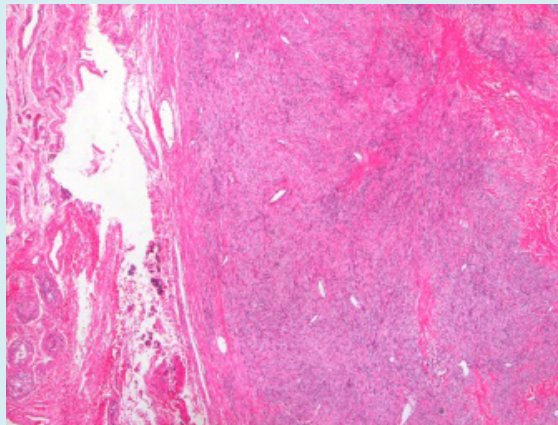
Commonly, neoplasm represents as a gradually progressive, unilateral testicular tumefaction. Associated hormonal modifications are extremely infrequent. Clinical countenance is benign. Tumour reoccurrence or distant metastases are absent [2,3]. Grossly, a well-defined, circumscribed, un-encapsulated, firm, tan, yellow or grey/white neoplasm is observed. Tumour magnitude varies from 0.5 centimetres to 7.6 centimetres. Cut surface is solid to cystic with focal haemorrhage. Exceptionally, testicular fibrothecoma emerges as an encapsulated tumefaction [3,4]. Upon microscopy, neoplasm configures fascicles or expounds a storiform or herringbone pattern. Additionally, a commingling of aforesaid patterns may be delineated. Tumefaction is encompassed within a collagen rich stroma

incorporated with miniature vascular articulations. Cellular density and collagen fibres are quantifiably variable [3,4].

Mitotic figures are minimal with  $\leq 5$  mitoses per 10 high power fields although figures of up to 10 mitoses per 10 high power fields may be observed. Tumefaction may be infiltrative and appears to enmesh circumscribing seminiferous tubules, a feature which refrains from influencing biological behaviour of the tumour [3,4]. Generally, tumefaction is devoid of Sertoli cell or granulosa cell component. However, miniscule aggregates of diverse sex cord cells may be observed. Sex cord stromal cell tumours of testis delineating  $> 1$  microscopic focus of various sex cord stromal cells may be categorized as mixed or unclassified neoplasms as the aforesaid tumours display possible emergence of distant metastasis, in contrast to classic fibroma. Upon ultrastructural examination, fibroma cells may simulate fibroblasts and myofibroblasts [4,5] (Figures 1 & 2).



**Figure 1:** Fibrothecoma of testis delineating a storiform pattern composed of spindle shaped cells surrounded by collagen rich stroma with innumerable blood vessels and foci of haemorrhage [6].



**Figure 2:** Fibrothecoma demonstrating fascicles of spindle shaped cells encompassed within a collagen rich stroma with several blood vessels and foci of haemorrhage [6].

Stage	T	N	M	S
Stage 0	Tis	N0	M0	S0
Stage I	T1-T4	N0	M0	SX
Stage IA	T1	N0	M0	S0
Stage IB	T2-T4	N0	M0	S0
Stage IS	Any T/TX	N0	M0	S1-S3
Stage II	Any T/TX	N1-N3	M0	SX
Stage IIA	Any T/TX	N1	M0	S0
	Any T/TX	N1	M0	S1
Stage IIB	Any T/TX	N2	M0	S0
	Any T/TX	N2	M0	S1
Stage IIC	Any T/TX	N3	M0	S0
	Any T/TX	N3	M0	S1
Stage III	Any T/TX	Any N	M1a	SX
Stage IIIA	Any T/TX	N1-N3	M0	S0
	Any T/TX	Any N	M1a	S1
Stage IIIB	Any T/TX	N1-N3	M0	S2
	Any T/TX	Any N	M1a	S2
Stage IIIC	Any T/TX	N1-N3	M0	S3
	Any T/TX	Any N	M1a	S3
	Any T/TX	Any N	M1b	Any S

**Table 1:** Prognostic Groups of Testicular Cancer as Per Union for International Cancer Control (UICC).

### Stages

- **Stage IA** is comprised of primary neoplasms confined to testis and epididymis. Microscopic evidence of neoplastic vascular or lymphatic invasion appears absent. Clinical examination or imaging demonstrates absence of distant metastasis. Following orchidectomy, serum levels of tumour markers appear within normal limits (Table 1) [4].
- **Stage IB** is constituted of neoplasms demonstrating localized invasion of primary tumour with an absence of distant metastasis.
- **Stage IS** delineates persistent elevation or enhancing serum levels of tumour markers following orchidectomy, thereby indicating subclinical metastatic disease or a germ cell tumour confined to contralateral testis.

Tumour cells appear immune reactive to inhibin, steroidogenic factor 1(SF1), smooth muscle actin (SMA), calretinin, SOX9, FOXL2, CD56 or vimentin. Neoplastic cells appear immune non-reactive to MIC2, CD34, KIT, keratin, human melanoma black 45(HMB45) antigen, Melan A, desmin or S100 protein [4,5].

Fibrothecoma of testis requires segregation from neoplasms such as fibrosarcoma, leiomyoma, neurofibroma, fibrous pseudo-tumour, solitary fibrous tumour, unclassified sex cord stromal tumour, myoid gonadal stromal tumour or granulosa cell tumour [4,5]. Testicular fibrothecoma can be appropriately discerned upon ultrasonography. Besides, evaluation of tissue samples obtained with surgical manoeuvres as orchiectomy appear cogent for tumour discernment [4,5].

### Conclusion

Hormone levels characteristically appear within normal range. Few secretory neoplasms may display elevated levels of serum testosterone or oestrogens [4,5]. Tumour markers as beta human chorionic gonadotropin ( $\beta$ HCG), alpha fetoprotein (AFP) or lactate dehydrogenase (LDH)) appear within normal range [4,5]. Upon imaging, a well-defined, solid, hypoechoic tumefaction may be observed. Alternatively, a heterogeneous tumefaction may emerge. Testicular fibrothecoma may be appropriately alleviated with diagnostic orchidectomy. Subsequently, meticulous observation is recommended. The essentially benign testicular fibrothecoma may exhibit enhanced mitotic activity. Nevertheless, figures of up to 10 mitoses per 10 high power fields appear devoid of adverse prognostic outcomes [4,5].

### References

1. Sayedin H, Chalokia R, Woderich R (2023) Hydrocele Masking Testicular Tumour With Extensive Nodal Disease: A Case Report and Literature Review. *Cureus* 15(8): e43455.
2. Algarni AM, Junejo NN, Alkhateeb SS, Al-Hussain TO (2021) Testicular Fibroma: A Case Report and Literature Review. *Urol Ann* 13(3):308-311.
3. Gaddam SJ, Chesnut GT (2023) Testicle Cancer. *Stat Pearls International*.
4. Kapoor M, Leslie SW (2023) Sex Cord Stromal Testicular Tumor. *Stat Pearls International*.
5. Rajpert-De Meyts E, Aksglaede L, Bandak M et al. (2023) Testicular Cancer: Pathogenesis, Diagnosis and Management with Focus on Endocrine Aspects. In: Feingold KR, Anawalt B, Blackman MR (Eds.), *Endotext*. South Dartmouth (MA): MDText.com, Inc.; 2000.
6. Image 1 and 2 Courtesy: Pathology outlines.

