



Forensic Implications of Adverse Drug Reactions in Schizophrenia A Case Series

Alghffar EA*

Radwan Forensic Consultant, Abha Medicolegal Center, Saudi Arabia

***Corresponding author:** Eman Abdelghafar Radwan, Radwan Forensic Consultant, Abha Medicolegal Center, Saudi Arabia

Case Report

Volume 11 Issue 2

Received Date: May 28, 2026

Published Date: June 29, 2026

DOI: 10.23880/ijfsc-16000462

Abstract

Antipsychotic medications are essential for managing schizophrenia, yet their severe adverse effects can precipitate critical clinical complications. This study analyzes ten clinical cases referred to the Forensic Medicine Department in Abha, Saudi Arabia, between February 2020 and February 2025, to investigate the direct link between antipsychotic side effects and subsequent forensic involvements, legal liabilities, or fatalities. A retrospective analytical study was conducted on ten schizophrenia patients (5 males, 5 females) aged 13 to 50 years. Clinical histories, psychiatric prescriptions, forensic medical examinations, and investigative police files were thoroughly reviewed. The psychiatric medications administered, exact mechanisms of injury, secondary clinical complications, and legal outcomes were examined. The ten cases evaluated, nine patients survived and one was deceased. The forensic audit revealed distinct patterns of complication: The study included cases of Suicidal Behavior & Legal Relief, Physical Injuries & Motor Deficits, Vulnerability & Sexual Assault, Severe Medical Malpractice Claims & Mortality. These show highlights severe diagnostic and monitoring vulnerabilities. In all cases, psychiatric treatments were initiated solely based on symptomatic and family complaints, without comprehensive psychological therapy, brain imaging (MRI), or routine organic monitoring. Antipsychotic side effects extend far beyond metabolic or motor changes; they act as primary drivers for traumatic accidents, extreme vulnerability to crime and mortality. There is an urgent need to mandate stringent metabolic, cardiac, and neurological monitoring protocols.

Keywords: Schizophrenia; Antipsychotics; Forensic Medicine; Abha; Neuroleptic Malignant Syndrome; Clozapine; Akathisia

Abbreviations

EPS: Extrapyramidal Symptoms; TD: Tardive Dyskinesia.

Introduction

Analytic study In the past five years, from February 2020 to February 2025 of Ten cases with severe complications primarily related to antipsychotic medication side effects have been admitted to abha Saudi forensic medicine

departments [1-10]. Schizophrenia defined as a chronic and severe mental disorder that affects how a person thinks, feels, and behaves. Individuals with schizophrenia often struggle with distinguishing between what is real and what is not, leading to a range of symptoms. These symptoms typically fall into three categories:

Positive Symptoms: These include hallucinations (seeing or hearing things that aren't there) and delusions (false beliefs not based in reality). Disorganized thinking and movement



disorders also fall into this category.

Negative Symptoms: These involve a reduction or absence of normal functions, such as a loss of motivation, a lack of emotion, and difficulty with speech.

Cognitive Symptoms [9]: These affect memory, attention, and executive functions Treatment. Medical drugs work by altering brain chemistry, primarily by blocking dopamine receptors, which helps to reduce psychotic symptoms like hallucinations and delusions. There are two main generations of antipsychotics.

While antipsychotics are crucial for managing symptoms, they can have significant side effects, some of which can lead

to serious health complications.

Common side effects include: Metabolic Side Effects [4-6] Weight gain, increased blood sugar, and elevated cholesterol levels are common developing diabetes and cardiovascular disease. Obesity Extrapyramidal Symptoms (EPS). These are motor side effects more common with first-generation antipsychotics and include: Akathisia. Inner restlessness and an inability to stay still. Dystonia: Involuntary muscle contractions and spasms. Parkinsonism: Tremors, rigidity, and slowed movement. Tardive Dyskinesia (TD): Involuntary, repetitive movements, often of the face, tongue, and limbs. TD can be permanent and severely impact quality of life..

Results

Case number	Gender	Age	status	circumstance
1	Male	23	Alive	Attempted suicide
2	Male	30	Alive	Attempted suicide
3	Male	33	Alive	Attempted suicide
4	Male	27	Alive	Car accident with fracture
5	Male	50	Alive	Fall on psychiatric hospital ground with tibial fracture
6	Female	13	Alive	Alleged sexual assault
7	Female	17	Alive	Alleged sexual assault
8	Female	30	Alive	Alleged sexual assault
9	Female	50	Alive	Passes to come then recovered after weak
10	Female	22	Deceased	Developed heart failure

Table 1: Ten Cases were Examined in the Past Five Years: Five Males and Five Females, Nine of Them were Alive and One was Deceased.

Three single young men with suicidal attempt in different times and circumstances. They were referred by the police on charges of attempted suicide (as it is consider a crime in Saudi Arabia, They referred after recovery, It was explained

to Investigating authority that the suicide attempts resulted from the side effects of psychiatric medications and that they were attempts beyond their control.

Cases	Age (Years)	Mechanism of Injury	Injuries Sustained	Remaining disability or recovery
Case 1	30	Threw himself from height	Pelvic fractures, left foot fractures	Limitation movement of the left hip and ankle joints.
Case 2	33	Self-inflicted stab wound	Non-penetrating abdominal stab wound	complete recovery
Case 3	23	Self-inflicted stab wound	Non-penetrating chest stab wound	complete recovery

Table 2: Suicide Attempt Cases: Live Male Patients.

Two cases of injury and a request to determine the percentage of disability. The first case a 27-year-old young man who sustained a simple fracture in the left clavicle while he was driving his car and colliding with a car in front of

him. This was due to his feeling of imbalance, drowsiness, and poor concentration, which are side effects of psychiatric medications.

The other case is for a 50-year-old man who has been detained in a psychiatric hospital for three years with a diagnosis of schizophrenia and suffers from Parkinson's disease (side effect of antipsychotic drugs) He moves with the help of nursing, although he was physically healthy when he entered the hospital. He fell to the ground while trying to walk alone in the hospital and sustained fissure fracture in the right tibia. Both cases recovered from the fractures without disability.

Five Female Cases

The first case was a woman in her fifties who was transferred from the psychiatric hospital to intensive care at Asir Central Hospital due to a coma caused by antipsychotic medications. A review of her medical file at the psychiatric hospital revealed that she had been taking three pills of both first- and second-generation antipsychotic medications for only two weeks. Patient developed Neuroleptic malignant syndrome.

schizophrenia medications for only two weeks. Patient developed Neuroleptic malignant syndrome.

She did not exceed the safe dose, and she entered a coma and regained consciousness a week after being admitted to Asir Hospital. Patient's family accused psychiatric doctors of medical malpractice. Her medical history revealed that she was a widow, her children were married, and she lived alone in a remote area. She began destroying some of the furniture in the house and speaking incoherently, so she was diagnosed with schizophrenia.

Three Cases of Sexual Assault

A table summarizing the details of the three female victims who experienced sexual assault, including their backgrounds and forensic findings:

Case	Age	Background	Mental Health Condition & Symptoms	Incident Details	Forensic Examination Findings
Case 1	13	Escaped from a psychiatric hospital in Abha	Diagnosed with schizophrenia, on medication. Exhibited mild depression, poor concentration, muscle pain, and spasms.	luring and sexually assaulted after escaping the hospital.	Evidence of sexual harassment (still virgin).
Case 2	17	Escaped from a psychiatric hospital in Abha	Diagnosed with schizophrenia, on medication. Exhibited severe depression, poor concentration, imbalance, muscle pain, and spasms.	Abducted and sexually assaulted after escaping the hospital.	Recent loss of virginity confirmed.
Case 3	30	Escaped from home	Diagnosed with schizophrenia, on medication. Exhibited mild depression, moderate concentration, imbalance, muscle pain, .	Luring and sexually assaulted after escaping home.	Evidence of sexual harassment (still virgin).

Table 3: The Details of the Three Female Victims who Experienced Sexual Assault, including their Backgrounds and Forensic Findings.

The last case is of a 22-year-old she is recently graduated from university she was on antipsychotic medication for two years, with periods of stopping the medication. In the last 3 months, she suffered from heart palpitations, easily fatigue and shortness of breath, in addition to severe depression. The psychiatrist kept changing her medications based on the complaint. She developed pneumonia, which required her to be admitted to the hospital five days before her death. In hospital they discovered that she was suffering from heart failure, noting that she did not suffer from heart disease before the psychiatric treatment. Upon reviewing her psychiatric medications, it was found that she was taking the highest permissible dose of clozapine. The case was examined by the forensic doctor as a natural death, and the family did not accuse the psychiatrist of medical malpractice.

Discussion

Although there was no complaint of medical negligence in the cases except in one case, but by taking the medical history I found the following

In all of the above cases, I found that psychiatrists' diagnoses were based on patient symptoms only and may be family complaints about the individual's nervous, rebellious, or suspicious behavior; without discussing the patient, or conducting behavioral therapy sessions.

Doctors neglect to discuss the circumstances surrounding the person. Some of them are in adolescence and rebellious, while others are suffering from harsh family circumstances,

loneliness, or even academic stress.

No MRI was performed on the brain. No periodic medical examinations were performed to detect any illness resulting from the side effects. Many patients complained from side effects without responding from doctors.

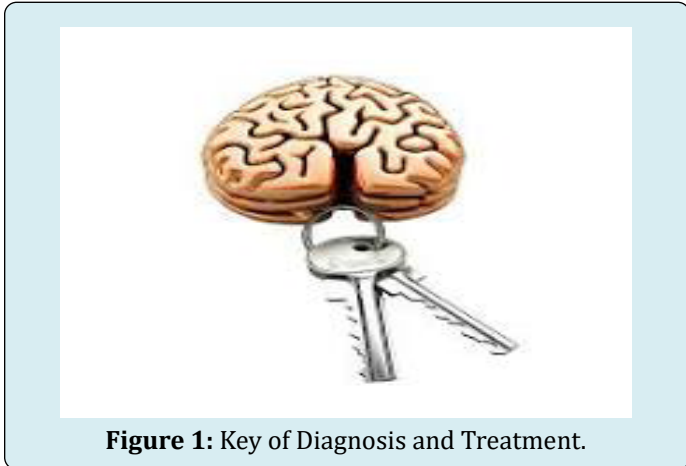

Figure 1: Key of Diagnosis and Treatment.

History American Psychiatric Association [1-2] Take a detailed medical history about the onset of symptoms and whether there are family, academic or emotional pressures and stress, whether the patient is a drug user or whether he has any chronic diseases . History of psychic trauma , head injury . All these help to detect the cause and the mood of therapy

Using MRI neuroimaging should done to detect SZ early and accurately. Many studies findings show that fMRI neuroimaging modalities provide physicians with important information about brain function, which helps to diagnose SZ accurately.

Recent studies Becker TM, et al. [3-7] using (fMRI) have identified significant disruptions in functional connectivity across multiple brain networks in schizophrenia, including the default mode, frontotemporal, and cerebellar networks [11-12]. These findings provide additional support for the dysconnectivity hypothesis, which suggests that impaired coordination between brain Also help to diagnosis of Brain tumors or damage to some brain cells which maybe the cause.

Knowledge more about brain cell a neurotransmitter these brain scans highlight dopamine receptors, with areas of highest density shown in red [16]. The meth (drug addict) abuser has severely reduced receptor levels. Other drugs, including alcohol, cocaine, and heroin, have the same effect [17].

Dr. Nora Volkow, Brookhaven National Laboratory

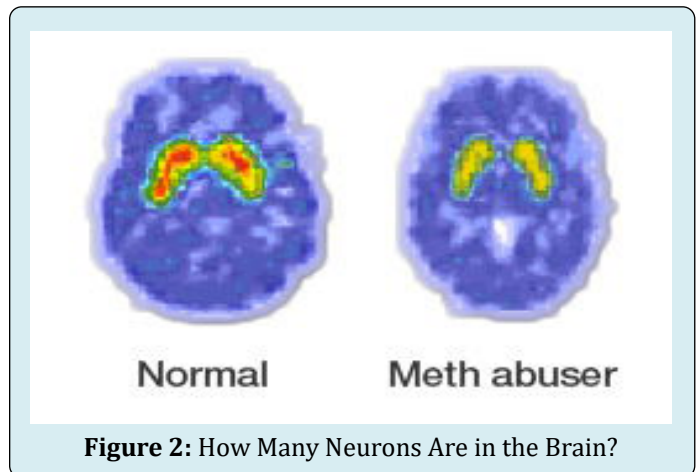


Figure 2: How Many Neurons Are in the Brain?

For half a century, neuroscientists thought the human brain contained 100 billion nerve cells. But when neuroscientist Suzana Herculano-Houzel devised a new way to count brain cells, she came up with a different number-86 billion.

Dopamine [8] is a neurotransmitter associated with movement, attention, learning, and the brain's pleasure and reward system. Dopamine is essential for many of our daily behaviors, playing a role in how we move, what we eat and learn. Two main brain areas produce dopamine. The substantia nigra and the ventral tegmental area, both located in the midbrain. The dopamine neurons are small in number (~0.0006% of the neurons in the human brain).

Currently, Dopamine [15] is known to have an essential role in nearly all cognitive functions, including motor control, motivation, and learning. Dysfunctions in dopamine neurotransmission are indeed a hallmark of most (if not all) psychiatric and neurological disorders, and pharmacological modulation of dopamine receptors, synthesis, and reuptake are widely used in clinical practice. In mammals, dopamine comprises 80% of the catecholamine content in the brain, making it the predominant neurotransmitter of its kind. Dopamine is also one of the oldest neurotransmitters, its function being extraordinarily conserved across nearly all animal species, from roundworms to humans.

Therefore, with this small number of dopamine cells in the brain, it is not preferable to give medications to block dopamine receptors, as well as block serotonin cell receptors, because in all cases, this leads to depression, difficulty thinking and movement, and many other side effects.

Conclusion

Ten cases were investigated at the Abha Forensic Medicine Department in various circumstances (injuries, sexual assault, suicide attempts, and death). It was found that these individuals were taking antipsychotic medications, and their side effects led to these incidents. Furthermore, it was discovered that the cases were diagnosed solely based on symptoms without performing functional MRI scans of the brain. These medications, despite their different types, work in a similar way: by blocking dopamine receptors and most also block serotonin receptors. It's worth noting that dopamine, as a hormone, is responsible for most brain and body activities, while serotonin is responsible for maintaining a balanced mood. Consequently, individuals taking these medications become withdrawn and lethargic, suffering from numerous health problems. This necessitates the following: firstly, accurate diagnosis, and secondly, exploring alternative treatment options, such as vitamins that aid in the development of neural networks.

Recommendations

- Good diagnosis by taking detailed history and making Braine MRI
- Never give antischizophrenic drugs for long period
- Accurate knowledge of side effects and how to deal with them
- Learn about modern medications that improve neural networks and help build nerve cells.

References

1. American Psychiatric Association (2021) Practice guideline for the treatment of patients with schizophrenia.
2. American Psychiatric Association (2022) Diagnostic and Statistical Manual of Mental Disorders. 5th Edn, Text Revision, American Psychiatric Publishing, Washington DC.
3. Becker TM, Kerns JG, Macdonald AW, Carter CS (2008) Prefrontal dysfunction in first-degree relatives of schizophrenia patients during a Stroop task. *Neuropsychopharmacology* 33: 2619-2625.
4. Carli M, Kolachalam S, Longoni B, Pintaudi A, Baldini M, et al. (2021) Atypical antipsychotics and metabolic syndrome: From molecular mechanisms to clinical differences. *Pharmaceuticals* 14(3): 238.
5. Cornett EM, Novitch M, Kaye AD, Kata V, Kaye AM (2017) Medication-Induced Tardive Dyskinesia: A Review and Update. *Ochsner Journal* 17(2): 162-174.
6. D'Souza RS, Hooten WM (2023) Extrapyrarnidal Side Effects. StatPearls Publishing, NCBI Bookshelf.
7. Gur RE, Keshavan MS, Lawrie SM (2007) Deconstructing psychosis with human brain imaging. *Schizophrenia Bulletin* 33(4): 921-931.
8. Health Direct (2022) Dopamine. Health Direct.
9. Javitt DC (2009) When doors of perception close: bottom-up models of disrupted cognition in schizophrenia. *Annual review of clinical psychology* 5: 249-275.
10. Leitman DI, Wolf DH, Ragland JD, Laukka P, Loughhead J, et al. (2010) It's not what you say, but how you say it: a reciprocal temporo-frontal network for affective prosody. *Front Hum Neurosci* 4: 19-31.
11. Meda SA, Stevens MC, Folley BS, Calhoun VD, Pearlson GD (2009) Evidence for anomalous network connectivity during working memory encoding in schizophrenia: an ICA based analysis. *PLoS One*.
12. Minzenberg MJ, Laird AR, Thelen S, Carter CS, Glahn DC (2009) Meta-analysis of 41 functional neuroimaging studies of executive function in schizophrenia. *Arch Gen Psychiatry* 66(8): 811-822.
13. Muench J, Hamer AM (2010) Adverse effects of antipsychotic medications. *American Family Physician* 81(5): 617-622.
14. Neuroscientifically Challenged. 2-Minute Neuroscience: Dopamine.
15. Science for Students (2022) Explainer: What is dopamine?
16. The Conversation (2022) Explainer: what is dopamine – and is it to blame for our addictions?
17. Dopamine (2022). Wiktionary.