



Parapharyngeal Lipomas: A Literature Review and Surgical Management

Patrick Hesketh*, Shadaab Mumtaz and Deepak Komath

Department of Oral and Maxillofacial Surgery, Royal Free London NHS Foundation Trust, London, United Kingdom

*Corresponding author: Patrick Hesketh, Department of Oral and Maxillofacial Surgery, Pond Street, London NW3 2QG, United Kingdom, Email: patrick.hesketh@nhs.net

Research Article

Volume 5 Issue 1

Received Date: November 26, 2021

Published Date: December 28, 2021

DOI: 10.23880/ijst-16000162

Abstract

Parapharyngeal space is a potential deep neck space extending between skull base and the hyoid bone. It is considered to be a rare site for neoplasms and it is even unusual to see Lipomas presenting in this space. Due to the proximity to skull base and presence of important structures in this space, surgical intervention can be complicated. An extensive literature review was carried out to comprehend the presenting features and management of this rare entity. Thirty-six reports/series were included presenting 37 patients between 15-83 years of age with a peak in 5th decade having lipoma in the parapharyngeal space/skull base region. The dimensions of these benign entities ranged between 3 cm to 16 cm. We present & discuss our experience with a large lipoma traversing parotid, submandibular and parapharyngeal spaces and its surgical management. We hope that this review and surgical principles presented will be helpful to the trainees and surgeons dealing with these entities.

Keywords: Parapharyngeal Lipomas; Mesenchymal Tumour; Lipoma

Introduction

Lipoma is the most common mesenchymal tumour (16%) in the body with about a quarter of these cases presenting in the head and neck region usually in the posterior neck [1]. Aetio-pathogenesis of this entity is unclear, however up to 80% of solitary lipomas were noted to have cytogenetic chromosomal alterations [2]. In patients presenting with recurrent or multiple lipomas, syndromic conditions such as Madelung disease, Dercum disease, Bannayan-Zonana syndrome, Familial multiple lipomatosis etc. should be excluded. The tissue itself consists of encapsulated adipocytes and connective tissue stroma. Some lipomas may present with atypical features such as thickened and increased septations with nodularity posing difficulties in diagnosis and surgical management [3]. Lipomas are seldom painful, and as such they often present with aesthetic concerns or compressive symptoms, at which time they are large indicating surgical intervention.

The Parapharyngeal space

The anatomical features of this complex inverted pyramidal space are presented below [4] (Figure 1):

- Boundaries
 - Superior: Skull base
 - Inferior: Hyoid bone
 - Anterior: Pterygomandibular raphe
 - Posterior: Vertebral fascia
 - Lateral: Medial pterygoid muscle
 - Medial: Superior constrictor

The space is divided by the styloid process into the pre-styloid and post-styloid compartments.

- Pre-styloid contents:
 - Ascending pharyngeal artery
 - Deep lobe of parotid gland
 - Minor salivary glands
 - Fat
- Post-styloid contents:

- Carotid artery
- Internal jugular vein
- Cranial nerves IX to XII
- Cervical sympathetic chain.

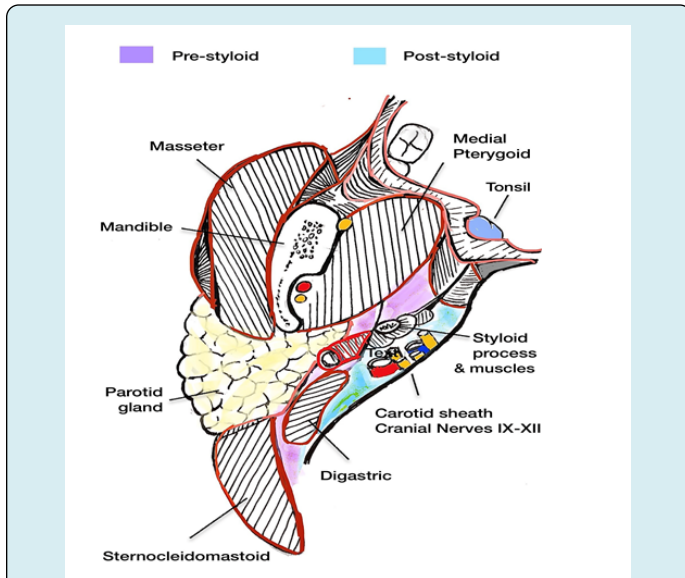


Figure 1: Anatomical representation of parapharyngeal space and its components (axial view).

Literature Review

A comprehensive English literature review was undertaken using PubMed, Medline and EMBASE databases using the term ‘parapharyngeal lipoma’ in both title and abstract between the periods of 1991-2021 (**Figure 2**). Literature without formal histological and/or cytological diagnosis was excluded to prevent ambiguity. Thirty-seven cases from 36 case reports and series (including the present case) were included in the review (**Table 1**).

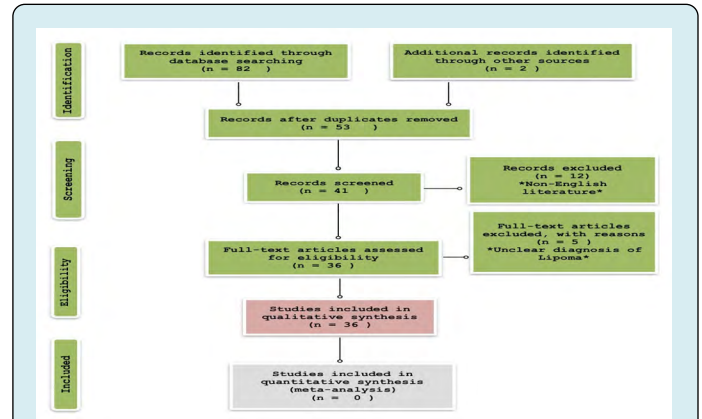


Figure 2: PRISMA flow diagram 2009 [5].

No	Year	Author	Age	Sex	Laterality	Dimensions (cm)	Type	Management	Recurrence
1	2020	Vijaykumar, et al. [6]	15	M	Left	5x4x3	Spindle cell lipoma	Excision	No
2	2020	Aslan, et al. [7]	20	M	Right	6 x 4.5	Simple lipoma	Transoral excision	-
3	2020	Lee, et al. [8]	-	F	Left	3x4x9.2	Simple lipoma	Transcervical excision	-
4	2020	Subramaniam. et al. [9]	54	M	Right	9.5 x 12.5 x 8.5	Sialolipoma	Transcervical excision	No
4	2019	Imai, et al. [10]	73	F	Left	9.5 X 5	Simple lipoma	Transcervical excision	No
5	2019	Azandaryani, et al. [11]	47	M	Left	5.5x4.5x3.2	Simple lipoma	Transcervical excision	No
6	2019	Marion, et al. [12]	69	M	Right	12.5 x 10 x 3.3	Simple lipoma	Transcervical excision	-
7	2018	Hakeem, et al. [13]	50	M	Left	24	Simple lipoma	Transcervical excision	No
8	2018	Maglione, et al. [14]	62	F	Left	5 x 3.5 x 2	Simple lipoma	Transoral robotic	No
9	2015	Pal, et al. [15]	40	F	Right	7x5	Simple lipoma	Transcervical excision	No
10	2015	Garcia-Ortega, et al. [16]	48	M	Right	16 x 12 x 2.5	Simple lipoma	Transcervical excision	-

11	2015	Aydin, et al. [17]	68	M	Right	-	Simple lipoma	Transcervical excision	-
12	2015	Luczak, et al. [18]	75	M	Right	8.5 x 5.8 x 7.2	Simple lipoma	Transcervical excision	No
13	2014	Chen, et al. [19]	45	M	-	6x7	Simple lipoma	Transmandibular	No
14	2013	Topak, et al. [20]	17	M	Left	6 x 5.5 x 3	Angiomyxolipoma	Transcervical/Tranparotid excision	-
15	2013	Chua, et al. [21]	71	M	Right	9.4 x 6.7	Simple lipoma	Transoral excision	-
16	2012	Casale, et al. [22]	70	M	Left	9 x 6	Simple lipoma	Transcervical excision	-
17	2012	Bulkele, et al. [23]	68	M	Left	4 x 1.5 x 1	Osteolipoma	Transoral excision	-
18	2012	Presutti, et al. [24]	61	F	-	3 X 1.5 X 1.8	Simple lipoma	Transcervical excision	-
19	2011	Crowso, et al. [25]	83	M	Left	-	Simple lipoma	Monitoring	-
20	2011	Crowso, et al. [25]	55	M	Left	13.6	Simple lipoma	Transcervical excision	-
21	2011	Bohm, et al. [26]	15	F	Left	3.8x3.5x2.8	Osteolipoma	Transoral excision	No
22	2009	Derin, et al. [27]	44	M	Right	5.5 x 7 x 2.5	Simple lipoma	Transparotid	No
23	2009	Kim, et al. [28]	75	F	Right	8 X 8	Simple lipoma	Transparotid	No
24	2006	McNeill, et al. [29]	75	M	Left	6 x 3	Simple lipoma	Monitoring	-
25	2006	Chen, et al. [30]	59	M	Left	4 x 2	Simple lipoma	-	-
26	2004	Erkan, et al. [31]	71	F	Right	5.5 x 4.5 x 3.5	Simple lipoma	Transcervical excision	-
27	2004	Ulku, et al. [32]	18	M	Right	-	Simple lipoma	Transcervical excision	No
28	2004	Singh, et al. [33]	38	F	Right	-	Simple lipoma	Transcervical excision	No
29	2003	Pelland, et al. [34]	53	M	Right	9 x 4 x 5	Simple lipoma	-	-
30	2002	Smith, et al. [35]	49	M	Left	-	Simple lipoma	Transcervical excision	No
31	2001	Baumann, et al. [36]	45	M	Right	7.5 x 3 x 6	Spindle cell lipoma	Transparotid	No
32	2001	Hazarika, et al. [37]	17	F	Right	5 x 4	Osteolipoma	Transcervical excision	No
33	1999	Scott, et al. [38]	69	M	Right	16 x 4.5 x 1.5	Simple lipoma	Transcervical excision	-
35	1995	Elanga, et al. [39]	55	F	Right	4.5 x 3.5 x 1	Simple lipoma	-	No
35	1994	Eckel, et al. [40]	54	M	Right	3 cm	Simple lipoma	Laser excision	-
36	1992	Higashi, et al. [41]	61	M	Right	9 x 7.5 x 3.5	Simple lipoma	-	-
37	2020	Present case	52	M	Left	9 x 6 x 2.5	Simple Lipoma	Transparotid/Submandibular	No

Table1: Literature review of parapharyngeal lipoma

Majority of the patients were males (71%) with average age of 52.46 years (Median 54 years). The smallest size reported was 3 cm and the largest was 9.5 x 12.5 x 8.5 cm in

maximum dimensions. Eighty-two percent of patients were histologically and/or cytologically diagnosed as having a simple lipoma. The other subtypes noted were spindle cell

lipoma, osteolipoma, angiomyxolipoma and sialolipoma. Half of the patients underwent transcervical excision (54%) and with transparotid, transoral & submandibular access being the other approaches used. A single patient was operated with Transoral robotic surgery for a lipoma of 5 x 3.5 x 2 cm maximum size [14].

Case Presentation

A 52 year old Nigerian gentleman presented with a progressively growing left neck mass since 18 months. He denied any odynophagia, dysphagia, dysphonia, weight loss or night sweats. His past medical history was significant for well-controlled diabetes mellitus for which he was on Metformin. He was a non-smoker and denied regular alcohol intake. Examination revealed a large swelling of the left sided parotid and submandibular region with smooth & non-erythematous overlying skin. All cranial nerves appeared intact. Intraoral examination noted fullness of the left parapharyngeal region. Magnetic resonance imaging (MRI) revealed a 9 x 6 x 2.5 cm homogeneous hyperintense mass involving left parotid, submandibular and parapharyngeal region abutting the base of skull (**Figure 3**). No other atypical features were noted.

The patient underwent excision with transparotid/submandibular approach and the histological evaluation diagnosed it as simple lipoma.

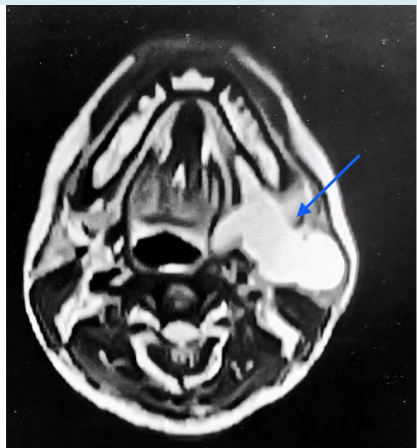


Figure 3: Axial MR image showing a large lipoma involving parotid, submandibular and parapharyngeal spaces.

Surgical Technique

Under general anaesthetic, a modified Blair incision with submandibular extension was made. Blunt and sharp subplatysmal dissection was undertaken. Facial nerve was carefully isolated and preserved with additional intra-operative monitoring (Medtronic™ nerve integrity monitor).

The submandibular gland was isolated and pushed medially to dissect part of the lipoma. The rest of the horse-shoe shaped lipomatous tissue was noted to extend to the parotid region with extension into the retromandibular region going towards the skull base. This was carefully excised with blunt meticulous surgical dissection (**Figure 4**). No intra-oral access was required. Two drains (Size 12 Redivac™) were inserted in parotid and submandibular region for 48 hours.

No immediate complications were noted in the post-operative period. Very minimal weakness of left marginal mandibular nerve was noted which improved after a few weeks (**Figure 5**). The patient was discharged with appropriate wound care instructions. No recurrence has been noted on 3 months follow-up.

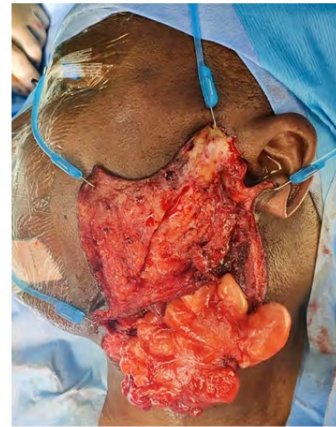

Figure 4: Surgical excision of the lipoma via Transparotid/Submandibular approach.




Figure 5: Two-weeks follow-up of the patient showing mild left marginal mandibular nerve weakness.

which however is not proven in our substantial review.

We have presented a detailed outlook of parapharyngeal space lipomas supplemented with largest review of literature pertaining to this subject available till now. It is hoped that this review will give more insight to the surgical trainees and surgeons in the field of otolaryngology and maxillofacial surgery.

Declarations

Conflict of Interests – none

Funding – none

Ethical approval – n/a

References

- Razek AA, Huang BY (2011) Soft tissue tumors of the head and neck: imaging-based review of the WHO classification. *Radiographics* 31(7): 1923-1954.
- Bartuma H, Hallor KH, Panagopoulos I, Collin A, Rydholm A, et al. (2007) Assessment of the clinical and molecular impact of different cytogenetic subgroups in a series of 272 lipomas with abnormal karyotype. *Genes Chromosomes Cancer* 46(6): 594-606.
- Bancroft LW, Kransdorf MJ, Peterson JJ, O'Connor MI (2006) Benign fatty tumors: classification, clinical course, imaging appearance, and treatment. *Skeletal Radiol* 35(10): 719-733.
- Day T, Albergotti G (2021) *Neoplasms of the Neck, Cummings Otolaryngology: Head and Neck Surgery (7th edn.)*, pp: 1764.
- Moher D, Liberati A, Tetzlaff J, Altman DG, The PRISMA Group (2009) Preferred Reporting Items for Systematic Reviews and Meta-Analyses: The PRISMA Statement. *PLoS Med* 6(7): e100009.
- Vijayakumar G, Kamboj M, Narwal A, Devi A, Singh V (2020) Bucco-Parapharyngeal Occurrence of Pleomorphic Spindle Cell Lipoma-A Unique Entity: Case Report. *J Clin Pediatr Dent* 44(2): 107-111.
- Aslan M, Ozturk EO, Dogukan FM (2020) A Rare Cause of Dysphagia: Giant Lipoma in Parapharyngeal Space. *J Craniofac Surg* 31(7): e667-e668.
- Lee HSH, Ngai CM (2020) Parapharyngeal space lipoma: a case report. *Hong Kong Med J* 26(5):438-440.
- Subramaniam S, Johan S, Hayati F, Ng CY, Azizan N, et al. (2020) Giant submandibular sialolipoma masquerading as huge goitre: a case report. *BMC Surg* 20(1): 130.
- Imai T, Nakazawa M, Uzawa N (2019) Lipoma Rarely Involving Multiple Suprahyoid Fascial Spaces: A Large Lesion Removed With Bimanual Transcervical Finger Dissection Using a “Push-Pull Down” Maneuver. *J Craniofac Surg* 30(8): e717-e719.
- Azandaryani AR, Eftekharian M, Taghipour M (2019) Large Laryngeal Lipoma with Extra Laryngeal Component Mimics Mixed Form Laryngocele: A Case Report. *Adv J Emerg Med* 3(4): e45.
- Marion F, Videlaïne A, Piot B, Merlet FL, Longis J, et al. (2019) A giant parapharyngeal lipoma causing obstructive sleep apnea. *J Stomatol Oral Maxillofac Surg* 120(6): 595-597.
- Hakeem AH, Hakeem IH, Budharapu A, Wani FJ (2018) Giant Parapharyngeal Space Lipoma Extending to the Pterygoid Region (Anterior Skull Base). *J Craniofac Surg* 29(2): e149-e150.
- Maglione MG, Guida A, Pavone E, Longo F, Aversa C, et al. (2018) Transoral robotic surgery of parapharyngeal space tumours: a series of four cases. *Int J Oral Maxillofac Surg* 47(8): 971-975.
- Pooja P, Bikramjit S, Arvinder S (2015) Unusual parapharyngeal lipoma. *Indian J Otolaryngol Head Neck Surg* 67(Suppl 1):158-160.
- Ortega DYG, Pedraza AG, Ortiz KL (2015) Parapharyngeal space lipomatosis with secondary dyspnea, dysphagia and disphonia. *Int J Surg Case Rep* 15: 54-56.
- Aydin O, Erdogan S, Derin S (2015) Parapharyngeal Space Lipoma. *J Craniofac Surg* 26(7): e658-659.
- Luczak K, Dorobisz K, Krecicki T, Janczak D, Chabowski M, et al. (2015) The Lipomatosis of the Parapharyngeal and Retropharyngeal Space: A Case Report. *Srp Arh Celok Lek* 143(7-8): 455-457.
- Chen WL, Wang WJ, Huang ZQ, Zhang DM (2014) Osteotomy in the vertical ramus outside the mandibular foramen for tumours in the parapharyngeal space. *J Craniomaxillofac Surg* 42(3): e29-32.
- Topak M, Develioglu ON, Celebi S, Caglar E, Kimiloglu E, et al. (2013) A rare tumor of the parapharyngeal space: angiomyxolipoma. *J Craniofac Surg* 24(5): 1724-1725.
- Chua DYK, Lim MY, Teo DTW, Hwang SY (2013) Retropharyngeal lipoma with parapharyngeal extension: is transoral excision possible? *Singapore Med J* 54(9): e176-e178.
- Casale M, Salvinelli F, Mallio CA, Frari V, Vincenzi B, et

- al. (2012) Upper airway study should always come before any sleep study in OSAS evaluation: a giant parapharyngeal lipoma behind OSAS. *Eur Rev Med Pharmacol Sci* 16 (Suppl 4): 106-109.
23. Bulkeley W, Mills OL, Gonzalvo A, Wong K (2012) Osteolipoma of the parapharyngeal space mimicking liposarcoma: a case report. *Head Neck* 34(2): 301-303.
 24. Presutti L, Molteni G, Malvè L, Marchioni D, Ghidini A, et al. (2012) Parapharyngeal space tumors without mandibulotomy: our experience. *Eur Arch Otorhinolaryngol* 269(1): 265-273.
 25. Crowson MG, Hoang J, Esclamado RM (2016) Rare cases of large parapharyngeal lipomas. *Am J Otolaryngol* 37(1): 54-58.
 26. Bohm KC, Birman MV, Silva SR, Lesperance MM, Marentette LJ, et al. (2011) Ossifying lipoma of c1-c2 in an adolescent. *J Pediatr Orthop* 31(5): e53-e56.
 27. Derin AT, Güney K, Turhan M, Ağirdir BV (2009) Parapharyngeal lipoma: a case report. *Kulak Burun Bogaz Ihtis Derg* 19(2): 95-98.
 28. Kim DS, Kwon H, You G, Jung SN (2009) Surgical treatment of a giant lipoma in the parotid gland. *J Craniofac Surg* 20(5): 1601-1602.
 29. McNeill EJ, Samuel PR, England S (2006) Lipoma of the parapharyngeal space. *J Laryngol Otol* 120(2): e9.
 30. Chen KTK (2006) Fine-needle aspiration of parapharyngeal lipoma. *Diagn Cytopathol* 34(1): 82-83.
 31. Erkan AN, Yavuz H, Yilmazer C, Özlüoğlu L, Bolat FA (2004) Radiology Quiz Case 2. *Arch Otolaryngol Head Neck Surg* 130(8): 997.
 32. Ulku CH, Uyar Y (2004) Parapharyngeal lipoma extending to skull base: a case report and review of the literature. *Skull Base* 14(2): 121-125.
 33. Singh PP, Sharma A, Gupta N (2004) Parapharyngeal space lipoma. *Indian J Otolaryngol Head Neck Surg* 56(2): 152-154.
 34. Pellanda A, Zagury S, Pasche P (2003) Parapharyngeal lipoma causing obstructive sleep apnea syndrome. *Otolaryngol Head Neck Surg* 128(2): 301-302.
 35. Smith JC, Snyderman CH, Kassam AB, Fukui MB (2002) Giant parapharyngeal space lipoma: case report and surgical approach. *Skull Base* 12(4): 215-220.
 36. Baumann I, Dammann F, Horny HP, Plinkert PK (2001) Spindle cell lipoma of the parapharyngeal space: first report of a case. *Ear Nose Throat J* 80(4): 244, 247-50.
 37. Hazarika P, Pujary K, Kundaje HG, Rao PL (2001) Osteolipoma of the skull base. *J Laryngol Otol* 115(2): 136-139.
 38. Scott RF, Collins MM, Wilson JA (1999) Parapharyngeal lipoma. *J Laryngol Otol* 113(10): 935-397.
 39. Elango S (1995) Parapharyngeal space lipoma. *Ear Nose Throat J* 74(1): 52-53.
 40. Eckel HE, Jungehülsing M (1994) Lipoma of the hypopharynx: pre-operative diagnosis and transoral resection. *J Laryngol Otol* 108(2): 174-177.
 41. Higashi K, Sarashina N, Okamoto T, Matsuki C, Heim S (1992) Supernumerary ring marker chromosome as a secondary rearrangement in a parapharyngeal lipoma with t(10;12)(q25;q15) as the primary karyotypic abnormality. *Cancer Genet Cytogenet* 64(2): 163-165.
 42. Murphey MD, Carroll JF, Flemming DJ, Pope TL, Gannon FH, et al. (2004) From the archives of the AFIP: benign musculoskeletal lipomatous lesions. *Radiographics* 24(5): 1433-1466.
 43. Ijichi K, Murakami S (2017) Surgical treatment of parapharyngeal space tumors: A report of 29 cases. *Oncol Lett* 14(3): 3249-3254.
 44. Miller FR, Wanamaker JR, Lavertu P, Wood BG (1996) Magnetic resonance imaging and the management of parapharyngeal space tumors. *Head Neck* 18(1): 67-77.
 45. Johnson CN, Ha AS, Chen E, Davidson D (2018) Lipomatous Soft-tissue Tumors. *J Am Acad Orthop Surg* 26(22): 779-788.

