

Osteometrical Study on Age Related Changes of the Skull of Yankasa Ram

Shehu SA^{1*}, Bello A¹, Danmaigoro A¹, Abdurashed HA¹, Atabo SM² and Mahmud MA³

¹Department of Veterinary Anatomy, Usmanu Danfodiyo University, Nigeria

²Department of Animal Health and Production Technology, College of Agriculture and Animal Science, Nigeria

³Department of Animal Health and Production Technology, Niger State College of Agriculture, Nigeria

***Corresponding author:** Shehu SA, Department of Veterinary Anatomy, Faculty of Veterinary Medicine, Usmanu Danfodiyo University, Sokoto, Nigeria, Tel: +2348066162551; Email: snshehu@gmail.com

Research Article

Volume 3 Issue 1

Received Date: April 24, 2019

Published Date: May 23, 2019

DOI: 10.23880/jhua-16000136

Abstract

There is dearth of information on the biometry, clinical and applied anatomy of the head region, general morphology on the indigenous breed of sheep in particular, hence led to the motivation behind this study. This study gives the first biometric description of the skull of Yankasa indigenous breed of sheep in Nigeria. Twenty five heads (5[0-6months], 5[6months- 1year], 5[1-2years], 5[2-3years], 5[3years- above]) were collected from purposively and randomly sampled Yankasa male sheep from a slaughter slab and processed for Biometrical investigation. Several biometrical measurements were recorded from each of the 25 skulls. From these, simple descriptive statistical analysis was obtained. The values obtained from these groups were increasing with ages. This study has described the biometric characteristics of the Yankasa sheep and concludes that a contribution for comparative model for other African local ovine breeds in general and Nigerian ovine breeds in particular has being made. Being the first study of its kind in Nigeria, it makes a significant contribution to a better understanding of the Yankasa sheep skull. It is envisaged that the results obtained in this study will be useful as baseline data in anatomical and archaeological studies

Keywords: Osteometry; Yankasa Ram; Age related changes; Skull

Introduction

Sheep (*Ovis aries*) are quadrupedal, ruminant animals typically kept as livestock. They are members of the order *Artiodactyla*, the even-toed ungulates. Although the name

“Sheep” applies to many species in the *genus ovis*, in everyday usage it almost always refers to *Ovis aries*. Domestic sheep differ from their wild relative, in several respects, having become uniquely ‘neotemic’ as a result of selective breeding by humans. Sheep contributes

enormously to the protein requirements of most developing countries [1]. In Nigeria, sheep are found predominantly in northern part of the country. Sheep and goat are seen as having secondary importance in relation to crops [2]. It is generally considered to be four breeds or races of sheep native to Nigeria, the Balami, Uda, Yankasa and West African Dwarf (WAD) [2]. The Yankasa breed has been the most extensively studied in Nigeria. The body colour is white with black patches around the eyes and usually black too. Rams have curved horns and a hairy white hair and ewes are polled [3]. Animal morphology shows considerable variation with respect to breed, age, sex, nutritional condition and environmental factors among others [4]. Thus, measurements are important tools for comparison. In order to achieve a more objective assessment, numerous metrical measurements need to be carried out [5,6]. Craniometrical studies are vital because the skull is considered to be the major element of the skeleton indicating taxonomic affiliation, and can give information on changes in animals arising from selective breeding [7]. In addition, craniometrical studies of domestic animals are commonly reported in scientific literature due to the fact that the comparative data is of value in osteoarcheology [8,9]. Data generated from skull biometry can be important in anthropology (Bokonyi 1974) [10], forensic studies (Adebisi 2008) [11], regional anaesthesiology (Olopade and Onwuka, 2005a) [12], taxonomy Habel [13] and comparative anatomical studies between and within breeds [14]. They are also important for classification, as the phenotypic appearance of an animal's head has been reported to depend on the shape of the skull and is strongly related to breed-specific skeletal features [5].

Many researches have been carried out to study the developmental changes in the skull of sheep, such researches included that of Kataba [15], Olopade and Onwuka [16], Muhamed, et al. [17] that worked on Gwembe Valley Dwarf goat, West African Dwarf and Barbados black belly Sheep respectively. However, in Nigeria there is paucity of information on the developmental changes in the skull and mandible of indigenous breeds of sheep. Therefore this study is designed to have revealed slight variation in general morphology of the skull at different age of development, so that problems associated with these bones are minimized in each age categories.

Materials and Methods

The study was conducted in Sokoto metropolis, the capital of Sokoto state of Nigeria [18]. A cross sectional

study design was used. Purposive sampling (Non-probability sampling) was used in this study based on Patton [19]. The fresh heads from slaughtered Yankasa sheep were selected based on the known breed characteristics, good health and lack of skeletal abnormalities [16,20].

Twenty five (25) sheep identified as Yankasa sheep aged 0-6months and older were collected from Sokoto modern abattoir. The sheep were selected based on apparent good health of animals noting characteristics such as lack of congenital deformities, scars or trauma on the skulls (heads) [16]. The sampling was stratified according to age, the age was estimated on the basis of the eruption of the permanent teeth as a guide [21]. Following slaughter, samples were severed at the occipito-atlantal joint, and placed in clean polytene bags according to their age. The heads were later processed for morphometric analysis in the anatomy laboratory of the Faculty of Veterinary Medicine at Usmanu Danfodiyo University Sokoto, Sokoto State, Nigeria.

S/N	Age	No. of sample
1	0-6months	5
2	6months-1year	5
3	1-2years	5
4	2-3years	5
5	3years-Above	5

Table 1: Age group classification.

Maceration of the Sheep Heads

The hot water maceration techniques as described by Simoens, et al. [22] were used in this study. The skin and most of the muscles were separated and eyes were enucleated using knives and scalpel blades from the fresh heads. Samples were heated at over 80°C for 1 hour in solution of polycaboxylate and anionic surfactant (detergent). Muscles of boiled heads were separated with the aid of forceps and scalpel in water following boiling. The boiled heads were left to stand in the detergent water for 30 minutes after which the separation of remaining muscles and ligaments of the heads was done. The heads were then rinsed in clean water.

Drying of Head (Skull)

The heads were sun-dried on the first day, but transferred to the anatomy laboratory for completion of the drying process for three (3) days.

Biometrical Measurements

Fifteen biometrical measurements were obtained on the entire twenty five Yankasa sheep skull using Butterfly measuring tape and were weighed with a digital weighing balance (Citizens Scale1 PVT, Ltd, model MP-600, with a sensitivity of 0.01g). The measurements were taken systematically according to the five age categories at the same time retaining the numbering corresponding to standard.

Skull Parameters (Cranium)

1. Skull weight: weighed with a digital weighing balance.
2. Skull length: from the rostral end of the alveolar process of the incisive bone to the occipital crest and divided into cranial and nasal skull lengths.
3. Cranial skull length: from the cranial border of the frontal bone cranially to the occipital crest.
4. Infra orbital foramina distance: width between the infra-orbital foramen.
5. Supra orbital foramina distance: Greatest width between the two supra-orbital foramen.
6. Medial canthus to supra orbital foramen: distance from the medial canthus to the supra-orbital foramen.
7. Medial canthus to infra orbital foramen: distance from the medial canthus to infra-orbital foramen.
8. Medial-lateral canthus (both left and right): width between the lateral and medial canthus of both left and right eyes.

Skull Parameters (facial part)

9. Nasal skull length: from the cranial edge of the maxillary bone cranially at the level of incisor tooth to cranial border of the frontal bone caudally.
10. Facial tubercle to infra orbital foramen: distance between the facial tuberosity to infra-orbital foramen.
11. Midpoint of the first upper premolar at its alveolar border to the infra orbital foramen.

12. Nasal process of incisive bone to infra orbital foramen.
13. Distance between the occipital condyles.
14. Distance between the jugular processes.
15. Naso incisive notch to infra orbital foramen.

Data analysis

The data were analyzed statistically using Microsoft office Excel 2007. Numerical data were presented in forms of tables as means and \pm standard deviation. Two tailed t-test to compare the different groups and a significance level of $P \leq 0.05$ was used for all the comparisons.

Results

The mean and standard deviation of Yankasa sheep cranial bone biometry values were determined. The mean skull weight (SW) of group 1, group 2, group 3, group 4, group 5 were found to be 175.40 ± 0.99 , 213.15 ± 0.35 , 257.15 ± 0.57 , 324.30 ± 1.27 , 546.05 ± 0.21 respectively, and all there were significant difference between all the groups with increase in age. The mean skull length (SL) of group 1, group 2, group 3, group 4, group 5 were 22.25 ± 0.99 , 23.90 ± 0.14 , 26.83 ± 0.71 , 30.05 ± 0.42 , 32.50 ± 0.99 respectively, this shows that the values increases with age with significant difference between the 5 groups ($p \leq 0.05$) last group has the highest value while the first group has the least value. The cranial skull length (CSL) and infra-orbital foramina distance (IFD) increases with age with significant difference ($p \leq 0.05$) between all the groups. The supra-orbital foramina distance (SFD) showed gradual increase with statistical difference ($p \leq 0.05$) between groups 1, 2 and 3. The distance between the medial canthus and supra-orbital foramen (MSF) and distance between the medial canthus and infra-orbital foramen (MIF) showed some relative increase with significant difference ($p \leq 0.05$) in group 3 only. Distance between the medial and lateral canthus (M-LC) of both the left and right eyes. In the left eye there are significant increase $p \leq 0.05$ in groups 1, 2 and 5, whereas in the right eye there are significant difference between all the groups (Table 2).

Number of parameter	Group1	Group2	Group3	Group4	Group5
1. SW	175.40 ± 0.99^a	213.15 ± 0.35^b	257.15 ± 0.57^c	324.30 ± 1.27^d	546.05 ± 0.21^e
2. SL	$*22.25 \pm 0.99^a$	$*23.90 \pm 0.14^a$	26.83 ± 0.71^c	30.05 ± 0.42^d	32.5 ± 0.99^e
3. CSL	15.17 ± 0.85^a	18.22 ± 0.85^b	19.71 ± 0.49^c	22.60 ± 0.28^d	23.41 ± 0.35^e
4. IFD	9.06 ± 0.28^a	10.20 ± 0.42^b	10.71 ± 0.07	11.13 ± 0.42^d	11.73 ± 0.21^e
5. SFD	5.60 ± 0.42^a	6.29 ± 0.85^b	6.61 ± 0.21^c	$*7.53 \pm 0.28^d$	$*7.62 \pm 0.29^d$
6. MSF	$*3.67 \pm 0.28^a$	$*3.78 \pm 0.14^a$	4.10 ± 0.14^c	$*4.51 \pm 0.35^d$	$*4.62 \pm 0.49^d$

7.	MIF	*6.43±0.28 ^a	*6.71±0.07 ^a	7.33±0.28 ^c	*7.90±0.28 ^d	*7.90±0.42 ^d
8.	M-L C					
A.	Left	3.43±0.35 ^a	4.20±0.14 ^b	*4.62±0.14 ^c	*4.68±0.14 ^c	4.83±0.42 ^e
B.	Right	3.53±0.42 ^a	4.44±0.28 ^b	4.67±0.00 ^c	4.91±0.21 ^d	4.91±0.49 ^e

abcde: means on the same rows with different superscripts are significantly different ($P \leq 0.05$).

**: superscripts show no significant different ($P > 0.05$).*

Table 2: Mean ± SD values of the cranial bone landmark of clinical importance.

KEY: SW: Skull weight(g), SL: Skull length(cm), CSL: Cranial skull length(cm), IFD: Infra orbital foramina distance(cm), SFD: Supra orbital foramina distance(cm), MSF: Medial canthus to supra orbital foramen(cm), MIF: Medial canthus to infra orbital foramen(cm), M-L C: Medial-lateral canthus(cm)

Group 1= 0-6months, **Group 2**=6months-1year, **Group 3**=1 year-2years, **Group 4**=2years-3years, **Group 5**=3years-Above

Facial Bone Land Mark of Clinical Importance

The biometrical value of facial bones of Yankasa sheep were measured as shown in Table 3. The skull weight (SW) was as described previously (table 2). The nasal skull length (NSL) of group 1, group 2, group 3, group 4, group 5 were 7.39±0.42, 8.20±0.42, 9.43±0.42, 9.61±0.14, 9.77±0.35 respectively, which showed arithmetical increase with age with significant difference between ($P \leq 0.05$) groups 1, 2 and 3. The distance between the facial tubercle to infra orbital foramen (FTIF), midpoint of the

first upper premolar to the infra-orbital foramen (MTFUP), Nasal process of incisive bone to infra orbital foramen (NPOI), Distance between the jugular process (DBJP), Nasoincisive notch to infra orbital foramen (NIN) all showed geometrical increase with age, and they all had showed significant difference ($P \leq 0.05$) between the with exception of Distance between the occipital condyles (DBOC) which showed significant difference ($P \leq 0.05$) between groups 1, 2 and 5 only (Table 3).

Number of parameter	Group1	Group2	Group3	Group4	Group5
1. SW	175.40±0.99 ^a	213.15±0.35 ^b	257.15±0.57 ^c	324.30±1.27 ^d	546.05±0.21 ^e
2. NSL	7.39±0.42 ^a	8.20±0.42 ^b	*9.43±0.42 ^c	*9.61±0.14 ^c	*9.77±0.35 ^d
3. FTIF	3.10±0.42 ^a	3.39±0.35 ^b	4.03±0.42 ^c	4.23±0.28 ^d	4.32±0.07 ^e
4. MTFUP	1.69±0.28 ^a	2.42±0.35 ^b	2.82±0.21 ^c	3.03±0.21 ^d	3.19±0.35 ^e
5. NPOI	4.92±0.35 ^a	5.34±0.49 ^b	5.63±0.14 ^c	6.69±0.21 ^d	6.93±0.42 ^e
6. DBOC	2.82±0.21 ^a	3.32±0.28 ^b	*3.63±0.21 ^c	*3.92±0.35 ^c	4.12±0.28 ^e
7. DBJP	4.32±0.21 ^a	5.42±0.21 ^b	5.59±0.28 ^c	5.93±0.35 ^d	6.15±0.21 ^e
8. NIN	4.14±0.21 ^a	4.91±0.42 ^b	5.82±0.14 ^c	7.24±0.14 ^d	7.54±0.07 ^e

abcde: means on the same rows with different superscripts are significantly different ($P \leq 0.05$).

**: superscripts show no significant different ($P > 0.05$).*

Table 3: Mean ±SD values of the facial bone landmark of clinical importance.

KEY: SW: Skull weight(g), NSL: Nasal skull length(cm), FTIF: Facial tubercle to infra orbital foramen(cm), MTFUP: Midpoint of the first upper premolar to the infra orbital foramen(cm), NPOI: Nasal process of incisive bone to infra orbital foramen(cm), DBOC: Distance between the occipital condyle(cm), DBJP: Distance between the jugular process(cm), NIN: Naso incisive notch to infra orbital foramen(cm).

Group 1= 0-6months, **Group 2**=6months-1year, **Group 3**=1 year-2years, **Group 4**=2years-3years, **Group 5**=3years-Above

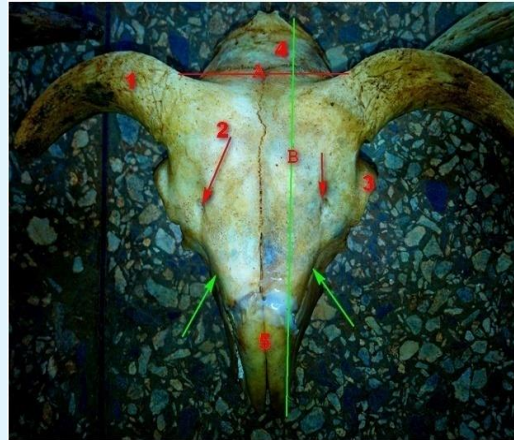

Plate 1: Dorsal view of the skull of Yankasa Ram showing: 1. Cornual process; 2. Frontal bone; 3. Orbit; 4. Inter parietal bone 5. Nasal bone; A. Width of the skull; B. Length of the skull; Red arrow. Supraorbital foramen; Green arrow. Infraorbital foramen.

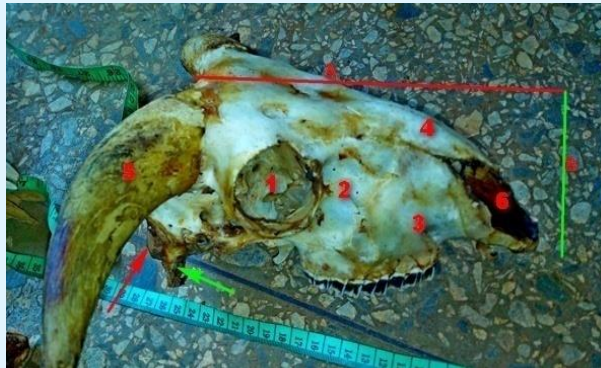

Plate 2: Lateral view of the skull of Yankasa Ram showing: 1.Orbit ; 2. Lacrimal bone; 3. Maxilla; 4. Nasal bone; 5. Cornual process; 6. Incisive bone; A. Length of skull; B. Height of skull; Green arrow. Jugular process; Red arrow. Occipital condyle.

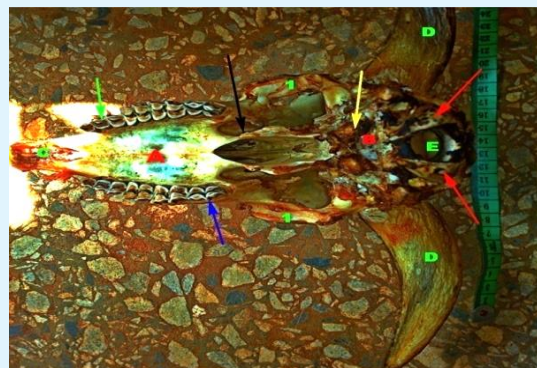


Plate 3: Ventral view of the skull of Yankasa Ram showing A. Maxilla; B. Occipital bone; C. Incisive bone; D. Cornual process; E. Foramen magnum; Blue arrow. Third molar; Green arrow. Second premolar; Black arrow. Pterigoid bone; Red arrow. Occipital condyle; Yellow arrow. Muscular tubercle; 1. Zygomatic bone.

Discussion

This study has documented the age related changes in the osteometry of the skull of Yankasa ram. Due to lack of information in the areas mentioned above on Yankasa sheep, the results obtained in this study is to form a baseline data for the Yankasa ram skull. It is envisaged that this baseline data will be useful for future studies in the *Ovinae* sub-family and other species of domestic animals in Nigeria. The implications and applicability of the results are discussed here under.

It is an established fact that bone growth in weight and length depends primarily on the amount of calcium salt deposited during ossification [23]. This in turn depends on the quantity of the mineral in animal feed, and the ability of the animal to use the mineral for bone calcification [24]. It is therefore, pertinent to point out that the nutritional status of animals from which the bone specimens collected were unknown. The values observed in the study showed significant difference in relation to the ages and the values were increasing with advancement in ages. The significant increase in weight of the skull was observed from three years and above, which showed how critical this period is in the growth and development of the animal. Therefore the need for adequate supply of necessary nutrients for growth and development and also to avoid diseases and abnormalities of the skeleton which occur due to mineral deficiency such as Rickets, osteoporosis and osteoarthritis among others. The values obtained for skull length by Muhamed, et al. [17], Olopade and Onwuka [16] and Kataba [15] in adult skull of Barbados Belly Sheep, West African Dwarf (WAD) and Gwembe Valley Dwarf goat were lower compared to what was recorded in this work.

The parameters for Nasal skull length, cranial skull length, Infra orbital foramina distance, Supra orbital foramina distance, Medial canthus to supraorbital foramina distance, Medial canthus to infraorbital foramina distance recorded for the adult group in this work disagree with adult parameters reported by Muhamed, et al. [17] but his report are in comparison with that of 6months and a year old reported for Yankasa sheep in this work.

The width of left and right orbit were observed to increase across the group in this work, The facial tubercle to infraorbital foramen of 6 month old Yankasa sheep in this work is equivalent to what was recorded by Muhamed, et al. [17] for adult Barbados Belly Sheep. The Nasal process of incisive bone to infra orbital foramen reported in this work agrees with the findings of

Muhamed, et al. [17]. The midpoint of the first upper premolar to the infra orbital foramen reported for adult Barbados Belly Sheep by Muhamed, et al. [17], disagree with the adult parameters in this work but equivalent to that of 6 months old in this work.

The Naso incisive notch to infra orbital foramen reported in this work disagree with the report from Muhamed, et al. [17], the distance between the occipital condyle and the distance between the jugular process were increasing with age in this work. These variations observed could be due to specie difference, environment as well as nutrition.

The distance between the lateral alveolar root to the mental foramen in the adult Yankasa sheep was not comparable to what was observed in WAD, Markhoz and Gwembe Valley Dwarf goats [12,15]. This distance in the present study, considering the first group was almost equivalent to what was observed in the Iranian Native goat [25] and Barbados Black sheep [17].

The differences observed in the morphometric measurements of the Yankasa sheep with other sheep and goats reported in literature could be due to the adaptations of skull structures to the environmental factors obtaining in these different geographic locations where the sheep and goats are found. This kind of adaptation has been reported in Eurasian wild boar which were of the approximate same age based on similar levels of tooth wear but showed skull size variation linked to their geographic location [26].

Conclusion

It will be concluded that the study on osteometry of Yankasa ram is comparable to other small ruminant; variations could be due to breed, age or sex. In addition, our work has provided baseline data on the skull osteometry of Yankasa ram that will be useful in anatomical and archaeological studies.

References

1. Muhammad N, Maigandi SA, Hassan WA, Daneji AI (2008) Growth performance and economics of sheep production with varying levels of rice milling waste. *Sokoto J Vet Sci* 7(1): 59-64.
2. Adu IF, Ngere LO (1979) The indigenous sheep of Nigeria. *World Review Ani Product* 15(3): 51-62.
3. Blench R (1990) *Traditional Livestock Breeds*;

- geographical distribution and dynamics in relation to the ecology of West Africa, Working paper 122, Overseas Development Institute Portland House, stag place London.
4. Alpak H, Onar V, Mustus R (2009) The relationship between morphometric and long bone measurements of the Morkaraman sheep. *Turk J Vetn Anim Sci* 33(3): 199-207.
 5. Künzel W, Breitand S, Opperl M (2003) Morphometric investigations of breed specific features in feline skulls and considerations on their functional implications. *Anat Histol Embryol* 32(4): 218-223.
 6. Brombin C, Mo G, Zotti A, Giurisato M, Salmaso L, et al. (2009) A landmark analysis-based approach to age and sex classification of the skull of the Mediterranean monk seal (*Monachus monachus*) (Hermann, 1779). *Anat Histol Embryol* 38(5): 382-386.
 7. Bruenner H, Lugon-Moulin N, Balloux F, Fumagalli L, Hausser J (2002) A taxonomical re-evaluation of the Valais chromosome race of the common shrew *Sorex araneus* (*Insectivora: Soricidae*). *Acta Theriologica* 47(3): 245-275.
 8. Guintard C, Fouche S (2008) Etude osteometrique de tetes osseuses de moutons (*Ovis aries*, L.). *Revue Méd Vét* 159(12): 603-617.
 9. Grigson C (1974) The craniology and relationship of four species of Bos. 1. Basic *Bostaurus* craniology: L. and its absolute size. *J Archaeol Sci* 1(4): 353-379.
 10. Bokonyi S (1974) History of Domestic Mammals in Central and Eastern Europe. Akademia ikiado, Budapest, pp: 597.
 11. Adebisi SS (2008) Contemporary tools in Forensic Investigations: The Prospects and Challenges. *Internet J Forensic Sci* 4(1): 1-8.
 12. Olopade JO, Onwuka S K (2005a) Some aspects of the clinical anatomy of the mandibular and maxillofacial Regions of the West African Dwarf Goats in Nigeria. *Int J Morphol* 23(1): 33-36.
 13. Habel RE (1975) Ruminant Introduction. In: Sisson & Grossman (Eds.), *The Anatomy of the Domestic Animals*, 5th (Edn.), WB Saunders, Philadelphia.
 14. Olopade JO, Onwuka SK, Kwari HD, Oke BO (2006a) Discovery of a depression on the cornual end of the temporal line of the skull of goat breeds in Nigeria. *Int J Morphol* 24(3): 349-350.
 15. Kataba A (2014) Biometric and morphologic characteristics of the skull of the Gwembe Valley Dwarf Goat (*Capra hircus*) Breed of Zambia.
 16. Olopade JO, Onwuka SK (2005b) Morphometric study of the skull of West African Dwarf Goat in South West Nigeria. *Nigerian Vet J* 26(2): 18-21.
 17. Muhamed R, Driscoll M, Mootoo N (2016) Clinical anatomy of the skull of the Barbados Black Belly sheep in Trinidad. *Int J Curr Res Med Sci* 2(8): 8-19.
 18. Sokoto BA (2001) The study of Local Geography of Nigerian secondary Schools, 1st (Edn.), Ministry of education Sokoto, pp: 104-110.
 19. Patton M (1990) Qualitative evaluation and research methods. Newbury Park: Sage Publication, pp: 244.
 20. Ahmadu B (2001) Management Practices, Morphometric Body Measurements and Diseases of Local Zambian Goats. PhD Thesis, The University of Zambia Lusaka.
 21. Vatta AF, Abbot MA, Villiers JF, Gumede SA, Harrison LJS, et al. (2006) Goat Keepers' Animal Health Care Manual. Agricultural Research Council. Onderstepoort Veterinary Institute with KwaZulu-Natal Department of Agriculture and Environment, South Africa, pp: 60.
 22. Simoens R, Poles R, Lauwers H (1994) Morphometric analysis of foramen magnum in pekingese dogs. *Ame J Vet Res* 55(1): 33-39.
 23. Richardson C, Herbert CN, Terileki S (1976) Estimation of the developmental age of the ovine foetus and lamb. *Vet Rec* 99(2): 22-26.
 24. Sivachelvan MN, Ghali M, Chibuzo GA (1996) Foetal age estimation in sheep and goats. *Small Ruminant Res* 19(1): 67-76.
 25. Monfared AL, Naji H, Sheibani MT (2013) Applied Anatomy of the Head Region of the Iranian Native Goats. *Global Veterinaria* 10(1): 60-64.
 26. Albarella U, Dobney K, Rowley Conwy P (2009) Size and Shape of the Eurasian wild boar (*Sus scrofa*) with the view of reconstruction of its Holocene history. *Environ Archaeol* 14(2): 103-136.

