

Terra Firma-Forme Dermatitis: About a Case

Sqalli HA* and Badreddine H

Dermatology and Venerology Department, Mohammed V University, Morocco

***Corresponding author:** Asmae Sqalli Houssaini, Dermatology and Venerology department, Hospital IBN SINA, Faculty of Medicine And Pharmacy, Rabat- Morocco, Tel : +212661311366 ; Email: sqalli_asmae@hotmail.com

Image Article

Volume 3 Issue 4

Received Date: June 06, 2019

Published Date: July 08, 2019

DOI: 10.23880/mjccs-16000232

Keywords: Hyperpigmented Plaque; Alcohol; Terra Firma

Image in Medicine

Terra firma-forme dermatosis, is a clinical entity whose etiology has still not been fully defined. It is characterized by the presence of asymptomatic, dirt like hyperpigmented plaques with a slightly papillomatous surface maybe due to disorder of keratinisation; these plaques cannot be removed with ordinary cleansing but disappear completely on swabbing with 70% ethyl or isopropyl alcohol.

We report the case of A 52 old female who had a hyperpigmented plaque in her neck that is evolving since several months. The interrogation revealed normal hygiene measures. Before any investigation, we suggest to make swabbing with 70% isopropyl alcohol. This procedure cleared the lesion, revealing skin of a normal appearance in the treated area which confirmed the diagnosis of Terra firma-forme dermatosis.

It is important to recognize this benign dermatologic condition since it can be confused with other cutaneous disorders in relation to various other hereditary or acquired dermatoses involving brown or grey

pigmentation including dermatosis neglecta or lichen pigmentosus. Therefore, in order to avoid unnecessary referrals, biopsies, blood tests, and medications, we suggest a trial of wiping the skin lesion with 70% isopropyl alcohol pads when the diagnosis of terra-firma forme dermatosis is considered.

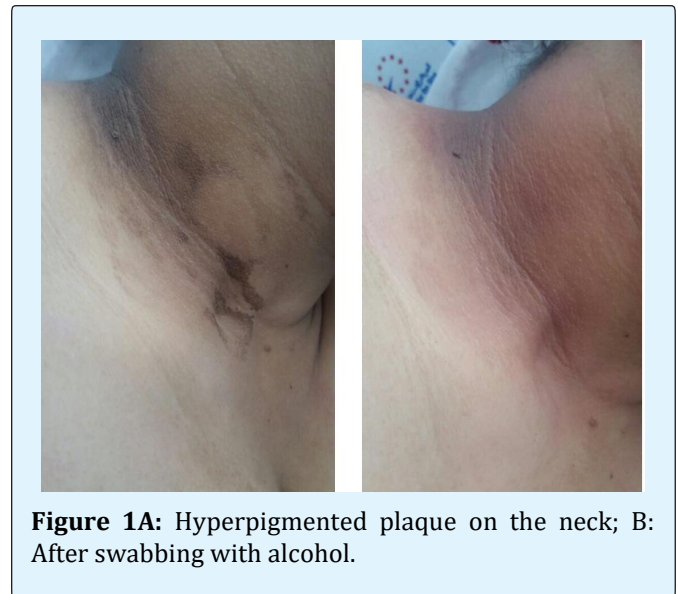


Figure 1A: Hyperpigmented plaque on the neck; B: After swabbing with alcohol.

