

# Retinopathy Stages Detection using Circular Hough-Transformation

Jyoti P<sup>1\*</sup> and Sharmila C<sup>2</sup>

<sup>1</sup>Research Center in Physics, Baburaoji Gholap College, India

<sup>2</sup>Annasaheb Magar Mahavidyalaya, India

**\*Corresponding author:** Jyoti Patil, Research Center in Physics, Baburaoji Gholap College, Sangvi, F-302, Nityanand Park, Vidyanagar, Lane No.1, Krushna Chowk, New Sangavi, Pune-411027 India, Tel: 7776078648; Email: jyot.physics@gmail.com

## Research Article

Volume 4 Issue 2

**Received Date:** April 18, 2019

**Published Date:** May 17, 2019

**DOI:** 10.23880/oajo-16000179

## Abstract

Diabetic retinopathy is progressive disease that leads patients to blindness. Diabetic retinopathy is classified into two main stages, namely non-proliferative diabetes retinopathy (NPDR) and proliferative diabetes retinopathy (PDR). In realism, there is not much difference in risk between diabetic eyes with normal eye and those having mild retinopathy. Both have a very low risk of progressing to PDR; in fact, the Early Treatment of Diabetic Retinopathy Study is necessary so that ophthalmologist can avoid severe stage. In this research used Circular Hough-Transformation method in which we find that sensitivity 89.25%, specificity 97.46 and accuracy 96.62%. It is found that the rate of progression to PDR after four years was less than 1% for both young and older patients with no diabetic retinopathy, compared to 4.1% in younger patients with a rare microaneurysm and hemorrhage.

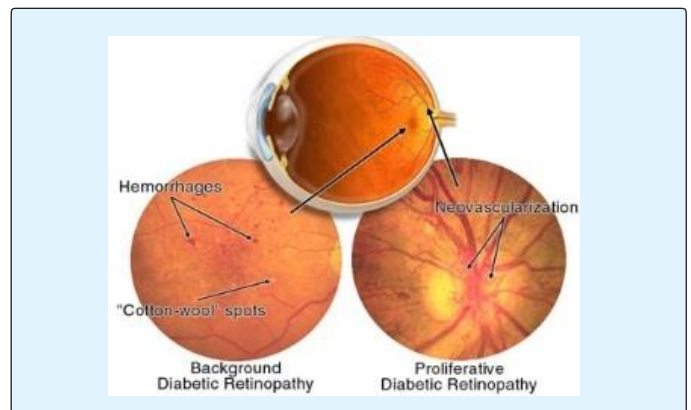
**Keywords:** Diabetic Retinopathy; NPDR; Microaneurysm; Hemorrhage

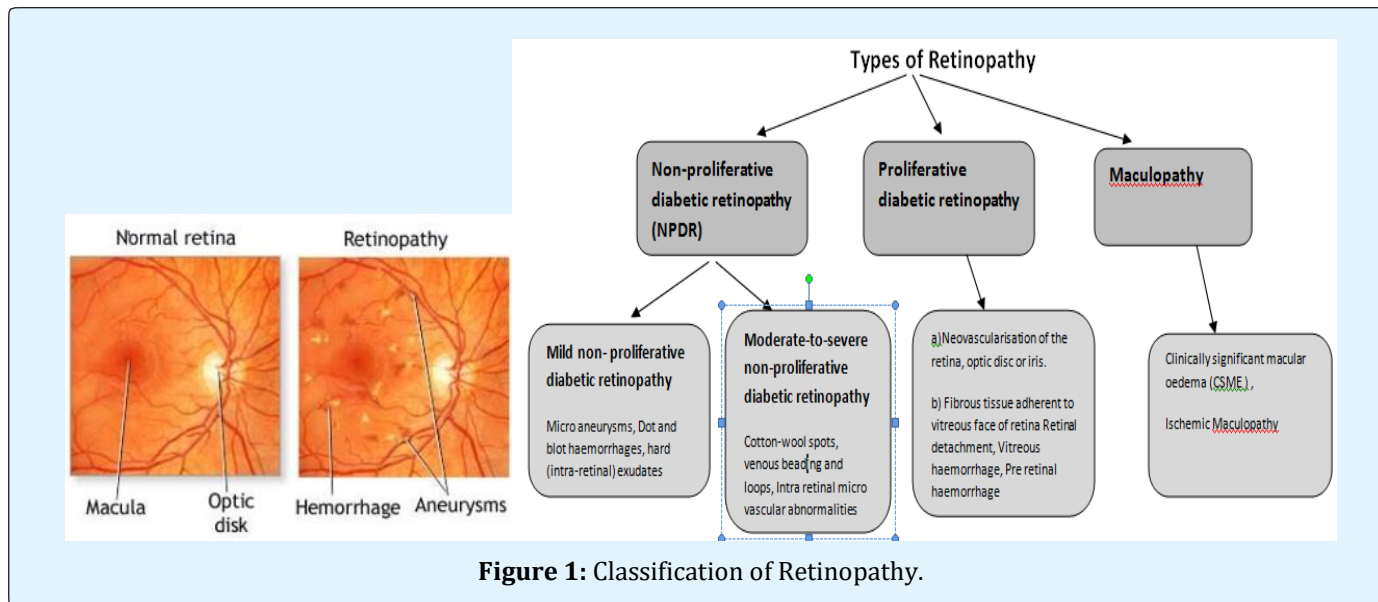
**Abbreviations:** NPDR: Nonproliferative Diabetes Retinopathy; PDR: Proliferative Diabetes Retinopathy; AMD: Age Related-Macular Degeneration.

## Introduction

### Classification of Retinopathy

Generally, diabetic retinopathy is classified into two main stages, namely nonproliferative diabetes retinopathy (NPDR) and proliferative diabetes retinopathy (PDR).

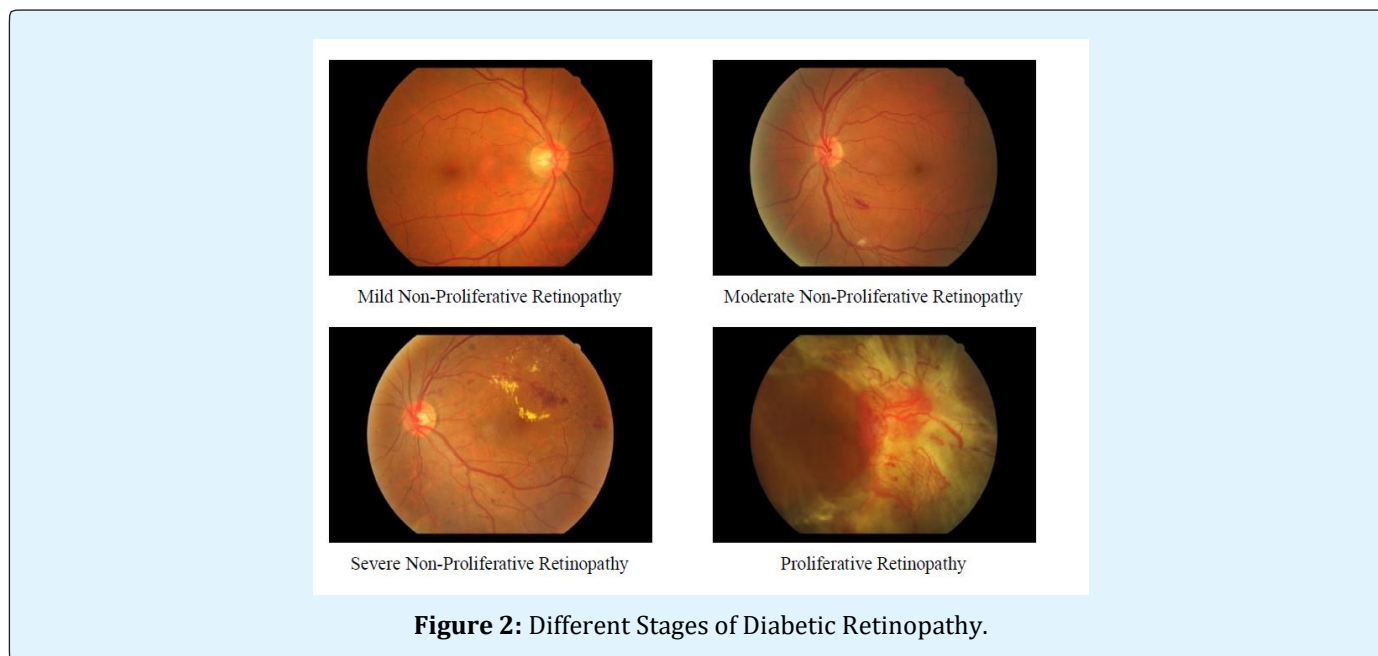




In NPDR, counting on the presence and extent of the options like onerous exudates, micro aneurysms or cotton wools spots because of outpouring of fluid and blood from the blood vessels, can be classified to mild, moderate or severe stages as followings: DR can be broadly classified as non-proliferative diabetic retinopathy (NPDR) and proliferative diabetic retinopathy (PDR), as shown in Figure 1. There are four DR stages: [2].

#### Pre-Proliferative DR

In this case, the changes are captured in the retinas which do not require much treatment but a little care should be taken which may lead to risk in progress which affects the eyesight.



**Stage 1: A. Mild Condition/ Mild NPDR:** This is the earliest stage of retinopathy and vision is sometimes traditional except in some cases. However, deterioration of the blood vessels within the tissue layer has already started. Blood vessels erupt when there is not enough oxygen in the blood because of high levels of glucose. At least one micro aneurysm with or without the presence of retinal haemorrhages, hard exudates, cotton wool spots or venous loops will be present. Small swellings known as Micro-aneurysms or flame-shaped hemorrhages start to develop in the fundus quadrants [1].

**Stage 2: Moderate NPDR:** As the disease progresses, some of the blood vessels that irrigate the retina become blocked. It is over “mild” however but “severe” stage. There will be micro-aneurysms or hemorrhages of greater severity in one to three quadrants and leakage might occur, resulting cotton wool spots and exudates etc. to be present in the retina. Moderate non-proliferative retinopathy. Numerous micro aneurysms and retinal haemorrhages will be observed. Cotton wool spots and a restricted quantity of blood vessel beading may be seen [2].

**Stage 3: Severe NPDR:** As a lot of blood vessels area unit blocked, those areas within the tissue layer are going to be empty blood offer. Signals will then be sent to the body for the growth of new vessels in order to compensate for the lack of nourishment. Severe non-proliferative retinopathy. Many options like haemorrhages and microaneurysms area unit gift within the tissue layer.

Other features are also present except less growth of new blood vessels; many more blood vessels are now blocked and these areas of the retina start to send signals to the body to grow new blood vessels for nourishment. Severe (more than 15) hemorrhages and micro-aneurysms in all four quadrants of the fundus. The malady would be thought of severe NPDR stage once any of the subsequent criteria area unit met:

- Definite venous beading in at least two quadrants
- Severe damage to the small blood vessels in at least one quadrant but no signs of any proliferative diabetic retinopathy.

**Stage4: Proliferative Diabetic Retinopathy:** PDR is the advanced stage whereby signals are sent by the retina to the body for the lack of blood supply and this triggered the growth of new blood vessels. These blood vessels will grow on the tissue layer and also the surface of the jelly-like substance (vitreous gel) that fills the centre of the attention. Although they are fragile and abnormal, they do

not cause symptoms or vision loss. It is only if their skinny and weak walls leak blood, severe visual loss or even irreversible blindness would occur [3].

3) Exudates (proteins and other lipids) and blood from the leakage forms around the retina and in some cases, leakage may form on the fovea, resulting in sudden severe vision loss and blindness.

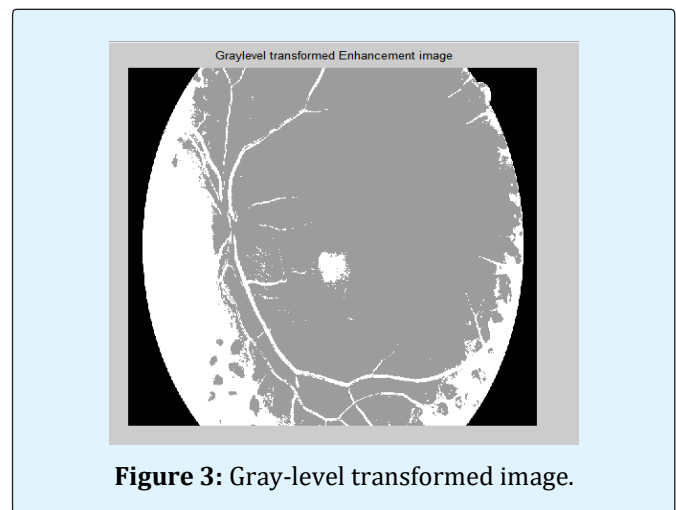
4) Proliferative DR comes when new vessels of blood occupy on overview portions of retina surface eventually. Thus the anomalous vessels will start bleeding then emerges from scar tissue leading to a brutal sight loss.

### Age Related-Macular Degeneration (AMD)

AMD is frequently observed retinal disease which occurs mainly in the people of the age of 50 and more. Macula a small dark portion near the middle of the retina is the exaggerated portion. Most of the people experience the effect of sight loss slowly but in some people, it is seen at the sooner phase a blurred region in the center portions of vision is a regular symptom.

### Walter-Klein Contrast Enhancement

This preprocessing technique aims to boost the distinction of structure pictures by applying grey level transformation victimization the subsequent operator:



**Figure 3:** Gray-level transformed image.

### Spencer, et al.

From the input complex body part image, the vascular map is extracted by applying twelve morphological top-hat transformations with twelve turned linear structuring components (with a radial resolution  $15^\circ$ ). Then, the vascular map is subtracted from the input image, which is followed by the application of a Gaussian matched filter. The ensuing image is then binarized with a set threshold

[4]. Since the extracted candidates aren't precise representations of the particular lesions, a district growing step is additionally applied to them.

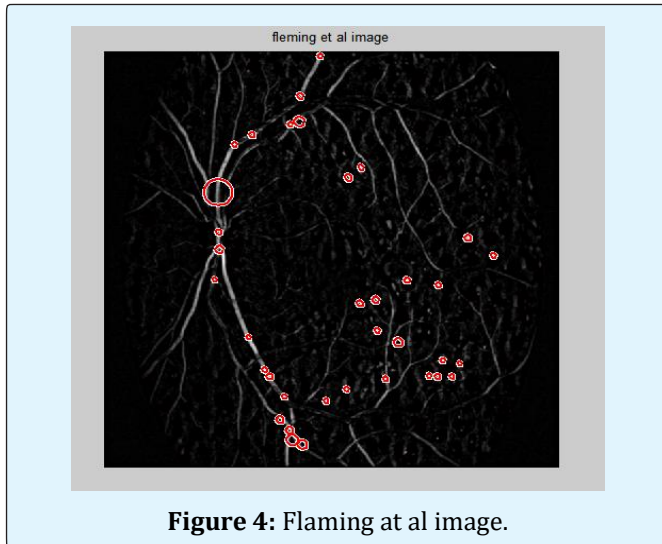


Figure 4: Fleming et al image.

### Circular Hough-Transformation

Following the thought conferred in, we tend to established associate approach supported the detection of tiny circular spots within the image. Candidates are obtained by detecting circles on the images using circular Hough transformation. With this system, a group of circular objects is extracted from the image.

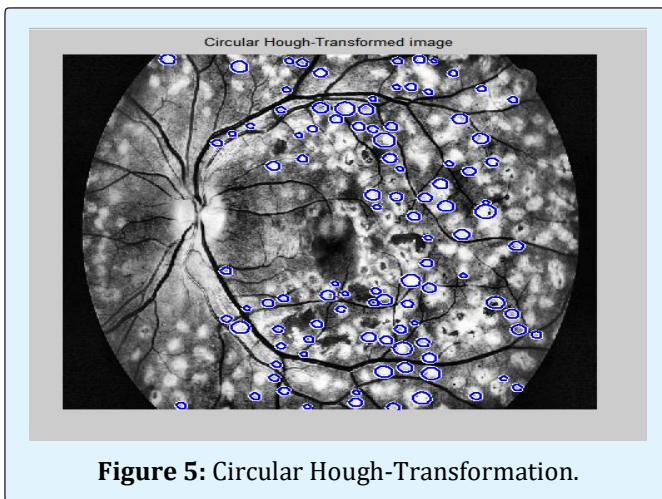


Figure 5: Circular Hough-Transformation.

### Zhang, et al.

In order to extract candidates, this technique constructs a highest correlation response image for the input retinal image. This is accomplished by considering the maximal correlation coefficient with five Gaussian

masks with different standard deviations for each pixel. The maximal correlation response image is threshold with a fixed threshold value to obtain the candidates. Vessel detection and region growing is applied to reduce the number of candidates, and to determine their precise size, respectively [5].




Figure 6: Zhang, et al.

### Lazar, et al.

Pixel-wise cross-sectional profiles with multiple orientations square measure accustomed construct a multidirectional height map. This map assigns a set of height values that describe the distinction of the pixel from its surroundings in a particular direction. In a changed construction attribute gap step, a score map is made from that the MAs square measure extracted by thresholding [6].

Author	Method	Dataset	Performance measure
Jyoti Patil	walter-klein contrast enhancement	MESSIDORE ,NIO,Drive	Sensitivity 89.25 % Specificity 97.46 % Accuracy 96.62 %
Vijay M.Mane	Thresholding Filtering	DIARETDB1	Sensitivity 96.42 % Specificity 100 % Accuracy 96.62 %
SophaK	Morphological Operators	ROC database	Sensitivity 80 % Specificity 99.5 %
Amiri	Circular hough Transform	OWN Database	Accuracy 88.5 %
Syed Ayaz	Local Thresholding Curvelet transform	ROC database	Sensitivity 48.21 %
Lama Seoud	Dynamic feature	shape ROC database	Sensitivity 93.3% Specificity 93.3 %
Harry Pratt	Convolution Network	Neural Kaggle Dataset	Sensitivity 95 % Accuracy 75%
IVO Soares	Coarser and finer Scale	ROC database	Sensitivity 47%
M Usman Akram	Multilayered Thresholding Filtering	Gabor ROC database	Sensitivity 97.83% Specificity 98.36% Accuracy 98.12 %




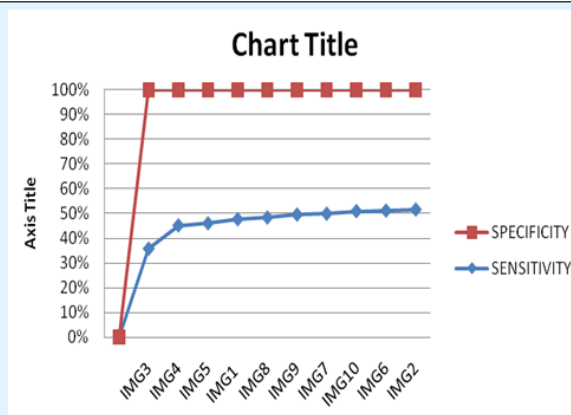


Figure 7: Lazar, et al.

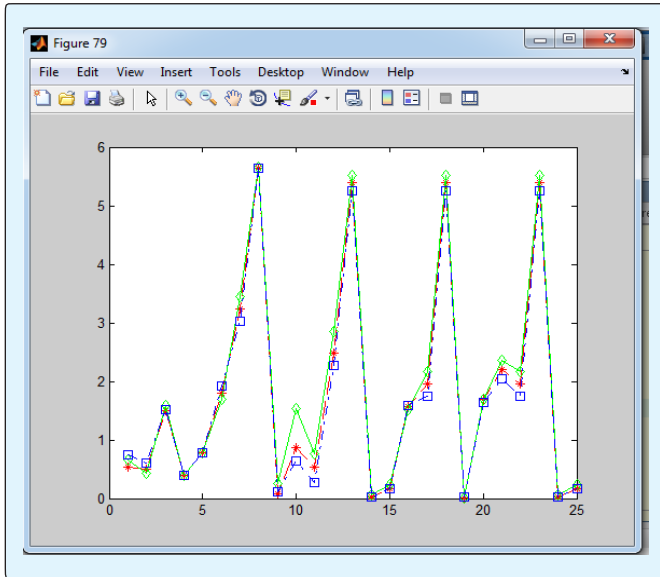
Sensitivity =  $[TP/(TP+FN)]*100 \rightarrow (1)$   
 Specificity =  $[TN/(TN+FP)]*100 \rightarrow (2)$   
 Accuracy =  $[(TP+TN)/(TN+FP+FN+TN)]*100 \rightarrow (3)$



Flow Chart 1: Results for different Candidate Extraction techniques.

IMAGE NO.	IMAGES	NO. OF LESION DETECTED	DISEASE CONDITION	MAIN TEST	SENSITIVITY	SPECIFICITY	FCM, LEVEL
Img 1			Mild Condition	5	0.90196	0.99359	FCM1, Level=0.539216
Img 2			Normal Condition	0	0.98879	0.93182	FCM1, Level=0.519608
Img 3			moderate condition	6	0.55556	0.9998	FCM1, Level=0.727451
Img 4			moderate condition	12	0.81818	0.99726	FCM1, Level=0.919763
Img 5			Mild Condition	1	0.84733	0.99664	FCM1, Level=0.490157
Img 6			Mild Condition	1	0.9862	0.94492	FCM1, Level=0.535294
Img 7			severe condition	49	0.96923	0.97615	FCM1, Level=0.594118
Img 8			mild condition	3	0.92537	0.99109	FCM1, Level=0.488235
Img 9			normal condition	0	0.94356	0.96355	FCM1, Level=0.496078
Img 10			normal condition	0	0.98434	0.95164	FCM1, Level=0.441176

Table 1: Results of the Performance Measurement Training Output 75 Value Plot (3 Images \*25 Combinations) 25 Combined Output-Entropy Values.



Depending on the measured feature values And based on the count of Red lesions, the image is classified as Normal/Healthy and Diseased and if it is diseased further sub-classified as Mild, Moderate and Severe. A pop up is displayed as follows.

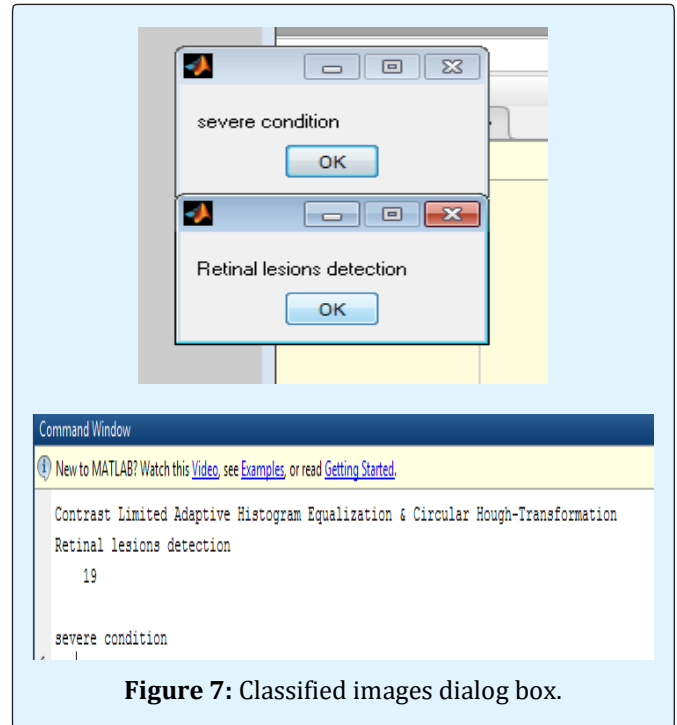
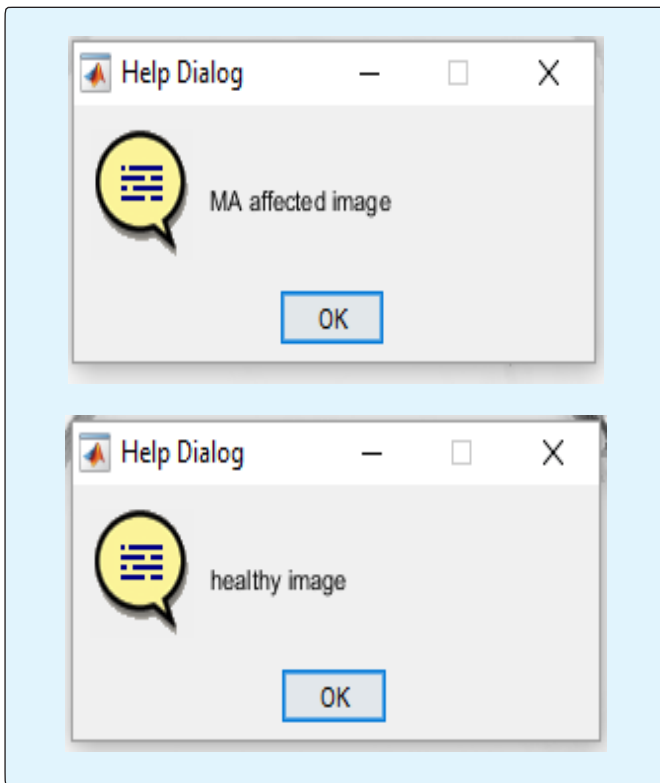


Figure 7: Classified images dialog box.

## Conclusion

We have measure the parameters like sensitivity, specificity and accuracy which determine stages of disease. This research used Circular Hough-Transformation method sensitivity 89.25 %, specificity 97.46 and accuracy 96.62 % which is based on the count of Red lesions, thus the image is classified as if it is normal, mild and severe stages of Diabetic retinopathy. Ultimately it can be dividing into non-proliferative diabetes retinopathy (NPDR) and proliferative diabetes retinopathy (PDR).

## References

1. Daniel Moges Tadesse (2014) An Automated Segmentation of Retinal Images for use in Diabetic Retinopathy Studies, Addis Ababa University.
2. Herbert J, Michael JC (2017) Automated Image Detection of Retinal Pathology.
3. Jyoti Pati (2013) Development of Digital Image processing tool. LAMBERT Publication, Germany, pp: 96.
4. Heikki K'alvi'ainen, Lappeenranta University of Technology Finland.

5. Ramasubramanian B, Prabhakar G (2013) An Early Screening System for the Detection of Diabetic Retinopathy using Image Processing. International Journal of Computer Applications (0975 -8887) 61(5): 6-10.
6. Color segmentation by Delta E color difference.

