



Ahmed Valve Implantation in Pseudophakic Refractory Paediatric Glaucoma - A Case Report

Umme Salma Akbar*, Shams Mohammed Noman and Shally Biswas

Department of Ophthalmology, Chittagong Eye Infirmary and Training Complex, Bangladesh

*Corresponding author: Umme Salma Akbar, Associate Consultant, Chittagong Eye Infirmary and Training Complex, Bangladesh

Case Report

Volume 6 Issue 2

Received Date: June 15, 2021

Published Date: July 12, 2021

DOI: 10.23880/oajo-16000225

Abstract

Purpose: To report a case of Ahmed valve implantation in pseudophakic refractory paediatric glaucoma.

Case Report: A 12 year old boy came to the Glaucoma clinic of Chittagong eye infirmary and training complex with secondary glaucoma resistant to pharmacological treatment in his right eye. Five years before, he underwent cataract extraction with implantation of posterior chamber intraocular lens in his right eye. On ocular examination, his BCVA was 6/60 in the right eye and 6/6 in the left eye. His IOP was 50mmHg in right eye and 16mmHg in the left eye on maximal anti-glaucoma medication. He then underwent Ahmed valve implantation in his right eye. Following the surgery, his visual acuity in the right eye was 6/36 and IOP was 12mmHg.

Conclusion: Ahmed valve implantation is a safe and effective modality of treatment for refractory glaucoma. Proper diagnosis and timely intervention can save the eye.

Keywords: Ahmed Valve Implant; Refractory Glaucoma; Anti-Glaucoma Medication; Pseudophakic Glaucoma; Neovascular Glaucoma

Introduction

Glaucoma drainage implants, including the Ahmed Glaucoma Valve have been used to treat complicated glaucoma such as aphakic or pseudophakic glaucoma, neovascular glaucoma, refractory glaucoma, no response to other glaucoma surgery, glaucoma associated with uveitis, glaucoma in Sturge-Weber syndrome, glaucoma following penetrating keratoplasty and traumatic and refractory glaucoma. In children, drainage implants have been used as an alternative to filtration surgery when angle surgery, such as goniotomy and trabeculotomy, has failed [1-6]. The Ahmed Glaucoma Valve Implant consists of a silicone tube connected to a silicone sheet valve held in a polypropylene body. The valve is designed to open at a pressure of 8 mmHg, decreasing the risk of postoperative hypotony [7]. The valve

was FP7 size with a total plate area of 184 mm² and a height of 2mm.

Our case report describes the safety and efficacy of Ahmed Glaucoma Valve implantation for the management of pseudophakic glaucoma in children.

Case Report

A 12 year old boy came to the Glaucoma clinic of Chittagong eye infirmary and training complex with secondary glaucoma resistant to pharmacological treatment in his right eye. Five years back, he underwent cataract extraction with implantation of posterior chamber intraocular lens in his right eye. On ocular examination, his BCVA was 6/60 in the right eye and 6/6 in the left eye. His

IOP was 50mmHg in right eye and 16mmHg in the left eye on maximal anti-glaucoma medication. He then underwent Ahmed valve implantation in his right eye. Following the surgery, his visual acuity in the right eye was 6/36 and IOP was 12mmHg which was maintained for a yearlong follow-up.

Surgical Method

The Ahmed Glaucoma Valve implantation procedure was performed under general anesthesia. A bridle suture was passed under the belly of superior rectus. The conjunctiva was undermined posteriorly by blunt dissection in the superotemporal quadrant to create a winged fornix-based conjunctival flap. The Ahmed Glaucoma Valve was primed before use. It was irrigated with 2ml of balanced saline solution through the tubing to open the valve mechanism.

The plate was then secured to the superficial sclera using two interrupted non-absorbable 9-0 nylon sutures with the anterior edge of the explant at least 8mm posterior to the limbus. These sutures were applied to prevent the migration of the plate and therefore of the tube. The tube was trimmed to extend from 1 to 3mm beyond the posterior surgical limbus. A 23-gauge needle was used to enter the posterior surgical limbus parallel to the iris plane and the anterior chamber in the superotemporal quadrant. The tube was inserted with a smooth forceps through the needle tract ensuring that no iris or corneal touch was present. The tube was then secured against the sclera using 9-0 nylon. The tube may occasionally erode through both sclera and overlying conjunctiva at the limbus. To avoid this, processed pericardium (Tutoplast) was sutured over the tube (Figure 1).

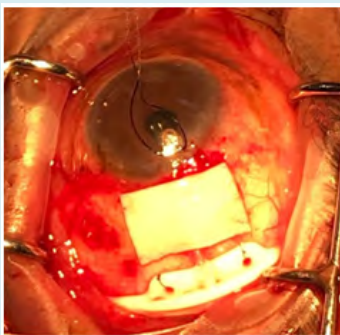


Figure 1: Per-operative picture showing tutoplast fixation.

Two sutures of 8-0 polyglactin (vicryl) were used to secure the conjunctiva and Tenon layers to peripheral cornea and to close the two wing incisions, respectively. Sub-conjunctival injections of antibiotics and corticosteroids were given at the end of surgery.

Our patient's follow-up was done on 1st post-operative

day, 7th post-operative day & 1month following surgery (Figure 2-4).

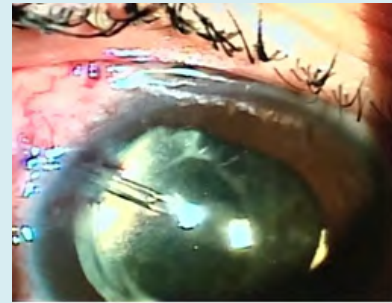


Figure 2: 1st post-operative day picture of Ahmed valve implant.

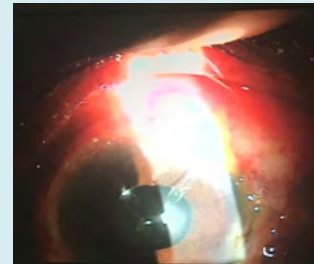


Figure 3: 1 week following Ahmed valve implantation.

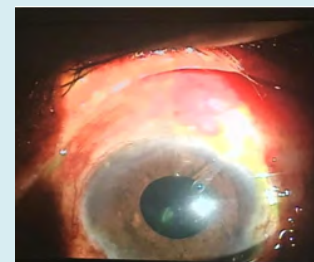

Figure 4: 1 month following Ahmed valve implantation.

Discussion

The management of refractory glaucoma's has considerably improved over the last 2 decades with advances in glaucoma drainage implant surgery [8]. Such devices allow a large surface area reservoir for the drainage of aqueous humour and provide a mechanism whereby aqueous humour may bypass excessive scar tissue formation at the limbus [8,9]. The Ahmed Glaucoma Valve implant is a valved polypropylene tube implant, which is designed to provide resistance to aqueous flow and decrease chances of severe postoperative hypotony that may be associated with the use of these devices [8]. Management of pediatric glaucoma, especially traumatic glaucoma, does not respond satisfactorily to medical treatment or filtering surgery [4].

Glaucoma drainage devices are used frequently to control intraocular pressure in complicated glaucomas [7].

The reported success rate of drainage implants in children varies from 44% to 95% Coleman AL, et al. [10] reported an overall success rate of 77% and 60.6% Englert JA, et al. [11] reported a success rate of 90.6% and 58.3% at 12 and 24 months, respectively, and Rosbach J, et al. [4] reported an overall success rate of 70% to 63% at 12 and 24 months, respectively in pediatric patients with Ahmed Glaucoma Valve implants.

The Ahmed Glaucoma Valve implant should be placed preferentially in the superotemporal quadrant as implantation of a large implant in the superonasal quadrant can lead to pseudo-Brown's syndrome [12] and has potential for contact with the optic nerve [13].

The main potential weakness of tube implant surgery is long-term encapsulation [14]. The Ahmed Glaucoma valve, because of its small surface area and polypropylene material, is potentially at higher risk of encapsulation than implants such as the Baerveldt shunt [15], which has a large surface area and silicone plate. In our case the child maintained a visual acuity of 6/36 and IOP of 12mmHg in the right eye for a year.

Thus, our case report confirmed that the Ahmed Glaucoma Valve may be safe and effective treatment for pseudophakic refractory glaucoma in children, despite its postoperative complications. This procedure may be used to treat complicated glaucoma in eyes with previous failed filtering procedures.

References

- Morad Y, Donaldson CE, Kim YM, Abdoell M, Levin AV (2003) The Ahmed drainage implant in the treatment of pediatric glaucoma. *Am J Ophthalmol* 135(6): 821-829.
- Djodeyre MR, Peralta Calvo J, Abelairas Gomez J (2001) Clinical evaluation and risk factors of time to failure of Ahmed Glaucoma Valve implant in pediatric patients. *Ophthalmology* 108(3): 614-620.
- Hamush NG, Coleman AL, Wilson MR (1999) Ahmed glaucoma valve implant for management of glaucoma in Sturge-Weber syndrome. *Am J Ophthalmol* 128(6): 758-760.
- Rosbach J, Choritz L, Pfeiffer N, Thieme H (2013) Clinical results of encapsulated bleb removal after Ahmed glaucoma valve implants. *Ophthalmologie* 110(8): 722-727.
- Wu SC, Huang SC, Lin KK (2003) Clinical experience with the Ahmed glaucoma valve implant in complicated glaucoma. *Chang Gung Med J* 26(12): 904-910.
- Montanez FJ, Laso E, Suner M, Amaya C (2005) Ahmed drainage device implant. Our experience between 1995 and 2003. *Arch Soc Esp Oftalmol* 80(4): 239-244.
- Malgorzata M, Anna B (2015) Ahmed Glaucoma Valve Implantation in the Surgical Treatment of Traumatic Glaucoma - Case Report. *J Ophthalmic Clin Res* 2(1): 1-2.
- Leuenberger EU, Grosskreutz CL, Walton DS, Pasquale LR (1999) Advances in aqueous shunting procedures. *Int Ophthalmol Clin* 39(1): 139-153.
- Ayyala RS, Zurakowski D, Monshizadeh R, Hong CH, Richards D, et al. (2002) Comparison of double-plate Molteno and Ahmed glaucoma valve in patients with advanced uncontrolled glaucoma. *Ophthalmic Surg Lasers* 33(2): 94-101.
- Coleman AL, Smyth RJ, Wilson MR, Tam M (1997) Initial clinical experience with the Ahmed Glaucoma Valve implant in pediatric patients. *Arch Ophthalmol* 115(2): 186-191.
- Englert JA, Freedman SF, Cox TA (1999) The Ahmed valve in refractory pediatric glaucoma. *Am J Ophthalmol* 127(1): 34-42.
- Coats DK, Paysse EA, Orenge Nania S (1999) Acquired pseudo-Brown's syndrome immediately following Ahmed Valve Glaucoma implant. *Ophthalmic Surg Lasers* 30(5): 396-397.
- Leen MM, Whitkop GS (1996) Anatomic considerations in the implantation of the Ahmed Glaucoma Valve. *Arch Ophthalmol* 114(2): 223-224.
- Das JC, Chaudhuri Z, Sharma P, Bhomaj S (2005). The Ahmed Glaucoma Valve in Refractory Glaucoma: experiences in Indian Eyes. *Eye (London)* 19(2): 183-190.
- Aung T, Seah SKL (1998) Glaucoma drainage implants in Asian eyes. *Ophthalmology* 105(11): 2117-2122.

