

Recurrent Post Tonsillectomy Hemorrhage: An Alarming Complication

Rifai M^{1*}, Younes A¹ and Hassan F²

¹Department of Otolaryngology, Medical school Cairo University, Egypt

²Department of Radiology, Medical school Cairo University, Egypt

***Corresponding author:** Mohamed Rifai, Department of Otolaryngology, Medical school Cairo University, Hoda Shaarawi Street, Bab El Louk 11111, Cairo, Egypt, Tel: 201208065566; E-mail: rifai29@gmail.com

Research Article

Volume 1 Issue 2

Received Date: July 06, 2016

Published Date: July 25, 2016

DOI: 10.23880/OAJ-16000111

Abstract

Objective: The aim of this study was to highlight the diagnosis and treatment of vascular injury as a rare cause of delayed resistant post-tonsillectomy hemorrhage, and the importance of both treatment modalities (surgical ligation and endovascular embolization).

Patients and Methods: This was a retrospective study of 11 patients who experienced delayed resistant post-tonsillectomy hemorrhages (DRPTHs). There were seven males and four females, with their ages ranging between four and seven years, and a mean age at presentation of four years old. Seven patients were treated using surgical ligation, while five underwent endovascular embolization.

Results: All 11 cases had idiopathic vascular abnormalities. Four of the patients developed pseudo aneurysms of the lingual artery, with one mainly in the linguofacial trunk. The other five patients had direct injuries to the walls of the lingual (three patients) and facial (two patients) arteries. Bleeding occurred between the 11th and 28th days after the tonsillectomies, and successful management included embolization (five patients) and surgery (six patients).

Conclusion: DRPTH is extremely rare, and deep suturing of the lower pole of the tonsil is the probable cause of the vascular injury. Early referral for embolization or open surgical exploration and ligation of the bleeding vessel is mandatory.

Keywords: DRPTH; Pseudo aneurysm of the external Facial and Lingual Arteries; External Carotid Artery Ligation

Introduction

DRPTH remains an unavoidable complication of the procedure, and could be lethal. These patients will present with either a history of bleeding or with active bleeding from the tonsillar fossa (e). Unfortunately, great differences exist in the reported incidence of post-tonsillectomy hemorrhage, the recommended management, and the very definition of what constitutes a

significant, DRPTH. Overall, a post-tonsillectomy hemorrhage is reactionary, primary, or secondary, and in rare instances, it is resistant to orthodox measures. These include oral rinses, the intravenous administration of fluids, the topical use of thrombin, ligation by sutures, and control in the operating room using suture ligation and/or bipolar electro cauterization. Many investigators have advocated the fact that, should local measures fail to control the bleeding, external carotid artery (ECA)

ligation or endovascular embolization may be a life-saving procedure. The bleeding in these patients has been recognized as being caused by pseudo aneurysms of the facial and lingual arteries [1-10].

Pseudo aneurysms may arise due to localized arterial wall lacerations caused by blunt or penetrating trauma. The intimal or adventitial layer of the vessel wall is dissected, creating a periarterial hematoma [8,11]. Here, we report on 11 patients who presented for evaluations following DRPTH, who all required interventions. Our aim was to highlight the possible causes of this morbid complication, and the importance of early decision-making regarding a referral to a tertiary care facility for possible open surgery or endovascular bleeding control.

Materials and Methods

The institutional review board of the Otolaryngology Department at Cairo University approved both the study design and the use of clinical data, and all of the patients' parents provided written informed consent. Overall, 11 patients presented with DRPTH to the ENT department of Cairo University over a period of 15 years. Seven of the patients were subjected to open surgical exploration. One of these patients was explored after the failure of endovascular embolization. Endovascular embolization was used for hemorrhage control in five patients, and proved successful in four. Arterial ligation was necessary to deal with the failure of the embolization in one patient.

Arterial Ligation

The neck on the bleeding tonsil side was explored through an incision along the anterior border of the sternomastoid muscle, and the subplatysmal flap was elevated. The common, internal, and external carotid arteries were identified, and the latter (ECA) was ligated using 2-0 silk below the origin of the ascending pharyngeal artery. The tonsil clamp is then removed and the tonsil bed examined to confirm the cessation of bleeding.

Endovascular Embolization

Endovascular Embolization became routine practice in our hospital by the end of 2007. Overall, five patients were subjected to interventional endovascular arteriography and subsequent embolization under general anesthesia. A conventional selective angiography of both the external and internal carotid arteries was initially performed.

The super selective catheterization of the parent artery was done using a Renegade (HI-FLO, Boston Scientific, USA) microcatheter. The endovascular embolization was performed via the injection of concentrated n-butyl 2-cyanoacrylate (NBCA) (Histoacryl) glue, diluted with Lipiodol at a 2:1 ratio, to fill the whole segment of the parent artery harboring the pseudo aneurysm with glue. Microcoils are the preferred material for the embolization of the artery harboring the pseudo aneurysm, since they allow the rapid effective occlusion of the injured artery with no risk of the inadvertent distal migration of the embolizing agent to the distal normal branches of the artery. Unfortunately, microcoils were unavailable on the shelf in our department, so we had to use Histoacryl glue. In all of the cases, the pseudo aneurysm was totally occluded in the segment of the artery harboring it. No distal infiltration of the branches of the injured artery occurred (Figures 1 and 2).

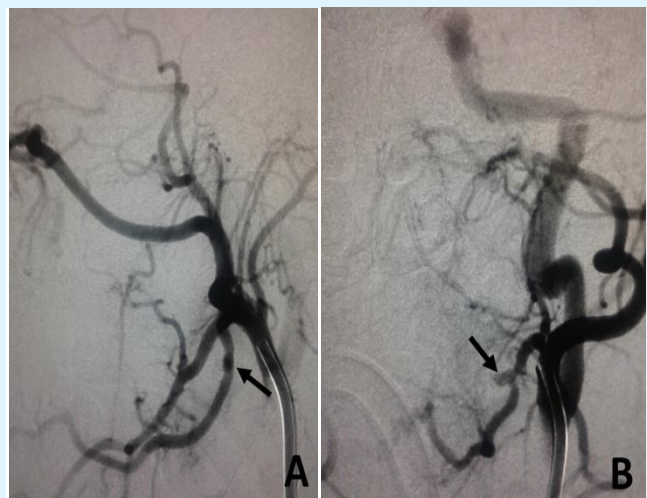


Figure 1: Lingual artery pseudo aneurysm, before embolization.

A) Left external carotid artery angiogram in the lateral view showing a small double density at the proximal segment of the lingual artery, suspected to be a small post-tonsillectomy pseudo aneurysm (black arrow).

B) Left external carotid artery angiogram in the anteroposterior (AP) view confirming the presence of a small lingual artery pseudo aneurysm (black arrow).

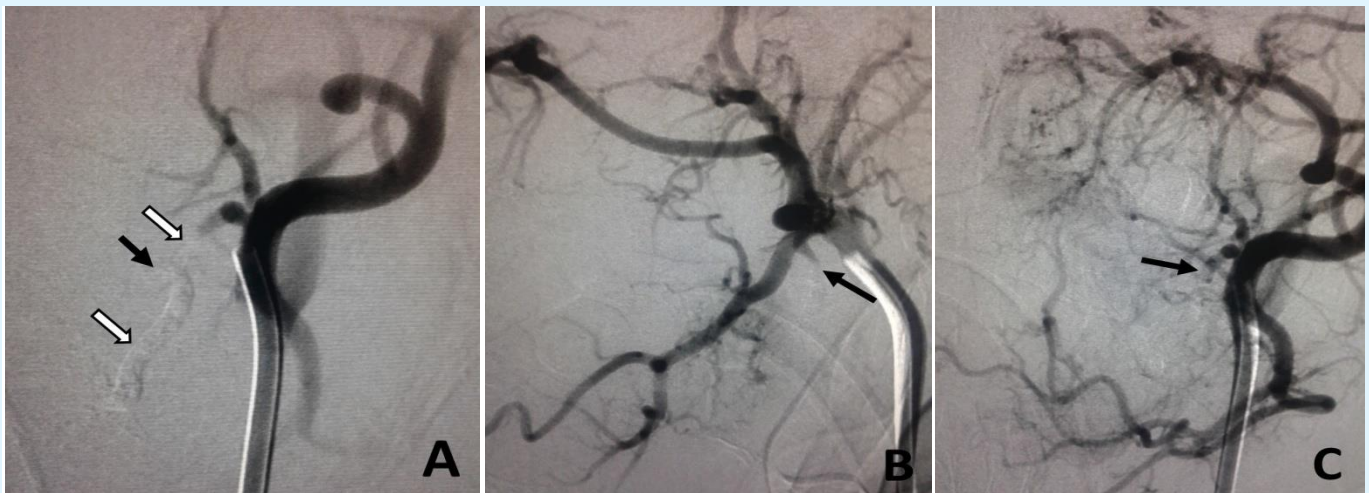


Figure 2: Lingual artery pseudo aneurysm, after embolization.

A) Left external carotid artery angiogram in AP view showing the cast of the Histoacryl glue, filling the small pseudo aneurysm (black arrow), as well as the segment of the lingual artery harboring the pseudo aneurysm (white arrows), with no significant distal infiltration of the branches of the artery.

B) Left external carotid artery angiogram in the lateral view showing occlusion of the pseudo aneurysm and the lingual artery. The stump of the lingual artery can be seen (black arrow).

C) Left external carotid artery angiogram in the AP view showing occlusion of the pseudo aneurysm and the lingual artery. The stump of the lingual artery can be seen (black arrow).

Three of the patients had active bleeding, which was evident via contrast extravasation during the diagnostic angiogram, and were controlled during the interventional procedure using tonsil compression forceps. The contrast extravasation disappeared after the injection of the embolizing material. Moreover, the removal of the forceps and examination of the tonsil bed after embolization was essential to confirm the success of the procedure. Furthermore, an immediate surgical exploration and ligation of the injured faciolingual trunk was necessary to deal with a failed embolization in one of these patients.

Results

Eleven patients with DPTH presented to the ENT department of Cairo University between December of 2001 and October of 2015. These included seven males and four females, with ages ranging between 4.2 and nine years old, and a mean age of 6.1 years old. One of the patients had his tonsils removed in our department, eight of the patients were operated on in private clinics, and two were operated on in a secondary care hospital. They were referred to Cairo University hospital after failure to control the postoperative bleeding. All of the patients

experienced recurrent bleeding episodes with spontaneous cessation. These episodes of bleeding usually began any time from the first to the twenty-second postoperative days. In seven cases, there were definite histories of using sutures to secure the bleeding at the lower pole during the tonsillectomy procedures. In four patients, we failed to trace the details of the surgical procedure. In one patient, visible sutures were detected on both tonsillar pillars, extending along the soft palate. Bulging of the soft palate was noted, with recurrent bursting of blood from one tonsillar fossa, under the suture site. Two of the patients were referred during their second postoperative days. They suffered frequent bursts of bleeding that were not controlled using conventional measures, including sedation, the application of IV fluids, tonsil compressing forceps, the removal of blood clots, topical thromboplastin and suturing, and/or cauterization under general anesthesia. The endovascular arteriography and embolization were performed under general endotracheal anesthesia, and oral packing was applied. The embolization was successful to control the bleeding in both of the patients.

Nine of the patients had recurrent episodes of hemorrhaging exceeding two weeks. These episodes ranged between five and nine attacks, and continued from two weeks to 28 days. Six of the patients presented during remission, while three of these patients presented to the emergency room with active secondary bleeding, and called for emergency management. The trans oral compression of the bleeding vessel was performed using a tonsil compression clamp, and the patient was immediately subjected to embolization. One patient had a recurrent episode of bleeding on the second day, and was subjected to open surgery under general anesthesia. The lingual artery was ligated; however, blood continued to ooze in the tonsil bed. This necessitated further ligation of the facial artery and pharyngeal vein. Seven patients had open surgical ligations of the external carotid artery and the bleeding artery. Additionally, in eight patients, a pseudo-aneurysm of the lingual artery was detected, while the pseudo-aneurysm was located in the linguofacial trunk in two patients. During the exploration in one patient, we could not define with certainty the nature of the vascular insult; however, the procedure succeeded in ceasing the episodes of bleeding, which had recurred for 28 days. In all of the cases, the procedures passed uneventfully, and all of the patients were discharged to their homes two to three days after the interventional procedures. No further attacks of bleeding occurred, and no morbid complications were recorded. Furthermore, no cases with lethal outcomes were encountered.

Discussion

In an attempt to minimize the incidence of post-tonsillectomy hemorrhages, many surgeons previously secured the lower pole of the tonsillar bed using sutures. Overall, a resistant DPTH deserves special consideration, and should draw attention to possible vascular injury; however, guidelines concerning the management of this mishap are deficient in the literature. Confusion often arises when the bleeding recurs and does not respond to the customary measures. Pseudo aneurysms were the cause of bleeding in 10 of the 11 patients discussed herein, and were usually the result of penetrating trauma to the arterial wall. The bleeding from the injured site resulted in a periarterial hematoma that became lined by a thin endothelial layer.

The increased volume and pressure subsequently resulted in a larger hematoma. This cycle may repeat, causing multiple episodes of severe bleeding [7]. The suturing of the faucial pillar is common practice in Egypt and many other countries. Although bipolar

electrocoagulation has been widely used in the past fifteen years, many surgeons apply sutures, especially to secure the lower pole of the tonsil as well. Bipolar electrocautery is not available in many secondary and some tertiary care hospitals and forgotten or overlooked surgical needles in the tonsillar fossae have been reported. Needles are used for hemostasis during a tonsillectomy, and may be broken and located at the lower pole [12-14]. An autopsy study of 15 lethal tonsillectomy patients identified deep wound necrosis, injury to the facial or descending palatine, lingual, or branches of the external carotid artery, and even arteritis dissecans of the internal carotid artery [15]. One study has suggested that the heat from laser-assisted instruments or electrocautery may create a deeper and more extensive zone of necrosis. Consequently, the authors refrained from placing deep trans oral sutures in cases with obvious wound necrosis, to prevent possible injury to the wall of the greater arteries running close to the necrotic wound surface, which may result in pseudoaneurysm formation with delayed brisk bleeding [15]. A post-tonsillectomy pseudo aneurysm can be treated by either the surgical ligation of the suspected bleeding vessel [1,3,10] or endovascular embolization [4-9]. Endovascular embolization carries the advantage of providing diagnostic angiography simultaneously, prior to therapeutic embolization. Accordingly, it allows more selective occlusion of the injured artery.

Conclusion

The ECA, with its branches, and the lingual and facial arteries run close to the tonsillar fossa. They are thus liable to iatrogenic injury during dissection or surgical ligation while performing a tonsillectomy. DPTH is a serious and morbid complication of tonsillectomy, and surgeons should suspect a pseudo aneurysm of the ECA branches in the case of a recurrent DPTH. A DPTH is treated by either open surgical ligation or endovascular embolization, with the latter having several advantages. Both the diagnostic angiographic assessment and subsequent intervention can be accomplished in the same procedure. An open surgical ligation is still an effective tool when interventional radiology is not handy, or in the case of a failed endovascular treatment. Recurrent DPTH is a serious complication, and the cessation of bleeding following recurrent episodes of brisk bleeding requires further intervention. An exploration of the carotid system or referral for endovascular angiography and embolization is mandatory.

References

1. Van Cruijssen N, Gravendeel J, Dijkers FG (2008) Severe delayed post-tonsillectomy haemorrhage due to a pseudo aneurysm of the lingual artery. *Eur Arch Otorhinolaryngol* 265(1): 115-117.
2. Windfuhr JP, Sesterhenn AM, Schloendorff G, Kremer B (2010) Post-tonsillectomy pseudo aneurysm: an underestimated entity? *J Laryngol Otol* 124(1): 59-66.
3. Karas DE, Sawin RS, Sie KC (1997) Pseudoaneurysm of the external carotid artery after tonsillectomy. A rare complication. *Arch Otolaryngol Head Neck Surg* 123(3): 345-347.
4. Menauer F, Suckfüll M, Stäbler A, Grevers G (1999) Pseudo aneurysm of the lingual artery after tonsillectomy. A rare complication. *Laryngorhinootologie* 78(7): 405-407.
5. Weber R, Keerl R, Hendus J, Kahle G (1993) The emergency: traumatic aneurysm in the area of the head-neck. *Laryngorhinootologie* 72(2): 86-90.
6. Mitchell RB, Pereira KD, Lazar RH, Long TE, Fournier NF (1997) Pseudo aneurysm of the right lingual artery: an unusual cause of severe hemorrhage during tonsillectomy. *Ear Nose Throat J* 76(8): 575-576.
7. Simoni P, Bello JA, Kent B (2001) Pseudo aneurysm of the lingual artery secondary to tonsillectomy treated with selective embolization. *Int J Ped Otorhinolaryngol* 59(2): 125-128.
8. Juszkat R, Korytowska A, Lukomska Z, Zarzecka A (2010) Facial artery pseudo aneurysm and severe bleeding after tonsillectomy-endovascular treatment with PVA particle embolization. *Pol J Radiol* 75(1): 88-91.
9. Manzato L, Trivelato FP, Alvarenga AYH, Rezende MT, Ulhoa AC (2013) Endovascular treatment of a lingual facial trunk pseudo aneurysm after tonsillectomy. *Braz J Otorhinolaryngol* 79(4): 524.
10. Gratacap M, Couloigner V, Boulouis G, Meder JF, Brunelle F, et al. (2015) Embolization in the management of recurrent secondary post-tonsillectomy hemorrhage in children. *Eur Radiol* 25(1): 239-245.
11. Franco KL, Wallace RB (1987) Management of postoperative bleeding after tonsillectomy. *Otolaryngol Clin North Am* 20(2): 391-397.
12. Gardner JF (1968) Sutures and disasters in tonsillectomy. *Arch Otolaryngol* 88(5): 551-555.
13. Gündüz K, Celenk P, Kayipmaz S (2004) An unusual foreign body (suturing needle) in the tonsillar region. *J Contemp Dent Pract* 5(4): 148-54.
14. Enoki AM, Testa JR, Morais Mde S, Fernandes DP, Tamiso SM (2010) Foreign body in the tonsillar region as a complication of tonsillectomy. *Braz J Otorhinolaryngol* 76(6): 796.
15. Windfuhr JP, Schloendorff G, Sesterhenn AM, Prescher A, Kremer B (2009) A devastating outcome after adenoidectomy and tonsillectomy: ideas for improved prevention and management. *Otolaryngology-Head and Neck Surgery* 140(2): 191-196.

