

Role of Endosulfan Dosing in Behavioural Changes and Testicular Toxicity in Swiss Albino Mice

Shashi Bhushan¹ and Ajay Kumar^{2*}

¹Research scholar, Department of Ceramic Engineering, NIT Rourkela, Orissa, India

²Research scholar, Department of Mining Engineering, NIT Rourkela, Orissa, India

***Corresponding author:** Ajay Kumar, Department of Mining Engineering, NIT Rourkela, Orissa, India, E mail: ajay3789@gmail.com

Short Communication

Volume 1 Issue 2

Received Date: August 05, 2017

Published Date: August 31, 2017

Abstract

Endosulfan has an organochlorine pesticide. It may impair the normal embryonic development and disrupt normal reproductive functions in adulthood. Experiments were conducted on swiss albino mice (*Mus musculus*) under controlled physical conditions of temperature, ventilation and cleaning. The experiment was conducted in polypropylene cages. Cages of two sizes, (a) small cage=26×19×13 cm and (b) large cage=40×25×15 cm were used. During treatment of endosulfan large cages were used, keeping two male and one female mice per cage. Endosulfan was supplied as 'Endosel' manufactured by Excel industries Limited, Mumbai, India at a concentration of 3.0 mg/Kg B.W. The oral administration (gavage method) of endosulfan to the mice for 30 days exhibited the behavioural and morphological changes, fall of body hair, rough and loose skin, restlessness and aggressiveness, bulging of eyes etc. 14 days after treatment (DAT), gradual loss of appetite and thirst, frequent rubbing of mouth with forelimbs was observed. After 30 DAT, mice became dull and sluggish. Increased incidence of stilted gait, hunched posture, irregular respiration and decreased spontaneous activity in males were observed. The inner anatomical observations suggested severe damage to histopathology of testis and appreciable modifications in reproductive organ anatomy.

Keywords: Endosulfan; Behavioural change; Toxicity

Introduction

Pesticides played significant role in bringing green revolution in India as well as in world. They are widely used to control agricultural pests and pests causing public health problems [1]. It is well established that the indiscriminate use of agrochemicals in modern agriculture not only poses severe health hazards for human beings but also has numerous other side effects on the environment including destruction of the biodiversity.

Endosulfan (Thiodon6,7,8,9,10,10-hexachloro-1,5,5a,6,9,9a-hexahydro-6,9-methano-2,4,3-benzodioxathiepin-3 oxide) is an organochlorine compound that is used as an insecticide and acaricide. It has become highly controversial agrochemical due to its acute toxicity, potential for bioaccumulation, and role as an endocrine disruptor. US Environmental Protection Agency (US EPA) classify it as Category-I: "Highly Acutely

Toxic” while WHO keep it in class -II “Moderately Hazardous” list.

It is banned in most developed countries e.g., USA, European Union and some developing countries of Asia and Africa but is being still extensively used for control of vectors in public health in Australia, Brazil, India etc [2-4]. India is World’s largest consumer of endosulfan. It is used in agriculture to control insects, pests, whiteflies, aphids, leaf hopper, colrado; wood preservation, home gardening etc. It is used primarily to kill insects and mites on crops including tea, coffee, cotton, fruits, vegetables, rice and other cereals [5]. Because of its non-specific effect, it can affect beneficial species members also and thus posing a risk to biodiversity. Endosulfan belongs to group of endocrine disrupting chemicals and acts like xenoestrogen. Endocrine disrupting chemicals (EDCs) are a structurally diverse group of compounds that may adversely affect the health of human being, wildlife and fisheries or their progenies, by interaction with the endocrine system (Fossi et al., 2007). It has been suggested that EDCs pose a potential risk and can alter the hormone balance in humans and wildlife (Ishibashi et al., 2001). These environmental xenobiotics may impair the normal embryonic development and disrupt normal reproductive functions in adulthood [6,7]. It persists in adipose tissues for decades and is biomagnified along food chain [8-10]. It is acutely neurotoxic to both insects and mammals, including human. It is also a xenoestrogen- a synthetic substance that imitates or enhances the effect of estrogens and can as endocrine disruptor, cause reproductive and developmental damage in both animals and humans.

The present experiment aimed to study the effect of endosulfan on overall animal behavior as well as histopathology of testis.

Experimental Design

The experiments were conducted on swiss albino mice (*Mus musculus*) under controlled conditions of temperature (24 ± 5 oC), light (alternate 12 hrs light and 12 hrs dark), proper ventilation and cleaning at Mahavir Cancer Sansthan and Research Centre, Patna, India (Reg. 1129/bc/07/CPCSEA).

The age group of mice selected for the study was 12 weeks old with 30 ± 2 gm body weight (b.w.). The experiment was conducted in polypropylene cages. Cages of two size, (a) small= 26X19X13 cm and (b) large cage= 40X25X15 cm were used. Endosulfan was supplied orally

(gavage method) as ‘endosef’ manufactured by Excel Industries Ltd, Mumbai, India at a concentration of 3.0 mg/Kg b.w. ; for 30 days. During treatment of endosulfan large cages were used, keeping two male and one female mice per cage. The control group of mice was supplied distilled water for drinking. The ‘treatment’ was supplied endosulfan 3mg/Kg b.w. daily by gavage method for five weeks. The variation in behavior from control was recorded daily. The mice were sacrificed after schedule treatment.

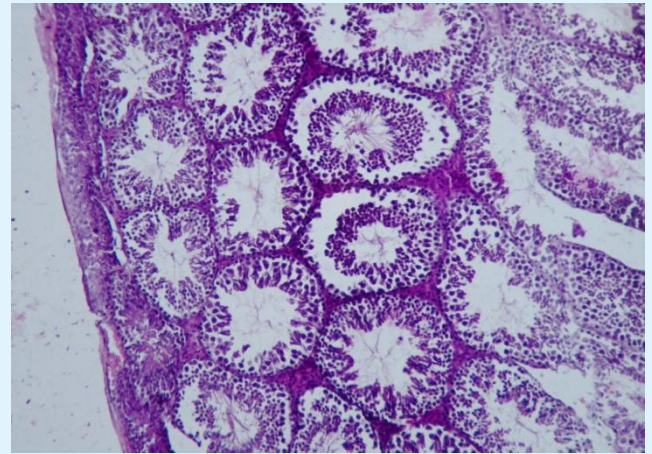


Figure 1a: Light micrograph of normal testis of Swiss albino mice showing well organized seminiferous tubule visible with different stage of spermatogonia, no gap between seminiferous tubules, and proper layer of tunica albuginea.

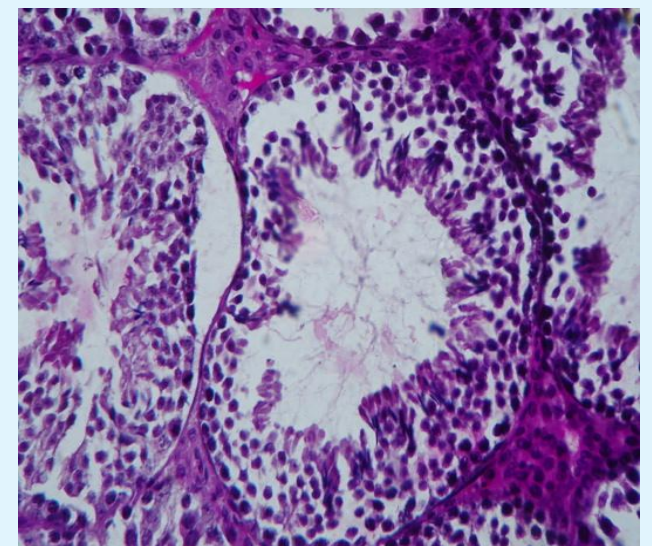


Figure 1b: Enlarge view of seminiferous tubules showing different stages of spermatogonia, primary and secondary spermatocyte, spermatids and spermatozoa.

Results

The oral administration of endosulfan to the mice for 30 days exhibited behavioral and morphological changes like loss of body weight, fall of body hair, rough and loose skin, restlessness and aggressiveness, budging of eyes which gave treated mice ugly appearance.

After 14 DAT, gradual loss of appetite and thirst, frequent rubbing of mouth with forelimbs was observed. After 30 DAT mice became dull and sluggish. Increased incidence of stilted gait, hunched posture, irregular breathing and decreased spontaneous activity in males were also observed. The inner anatomical observations suggested severe damage to histopathology and

appreciable modifications in reproductive organ anatomy of male mice (Figure 2 and Figure 3).

Sertoli cells of control mice show well organized nucleus. Nuclear membrane was also continuous (Figure 1a,1b). Sertoli cells of five weeks endosulfan administered mice show many osmiophilic granules condensed in cytoplasm. Degenerated tail of spermatozoa was also observed (Figure 2). Deshaped nucleus and degenerated mitochondria were clearly observed with many vacuolated spaces (Figure 3). Degenerated plasma membrane of sertoli cells was observed. Nourishing spermatozoa were clearly observed with degenerated acrosome.

Light micrograph showing longitudinal section of testis of endosulphan at 3mg/Kg body weight/day for 30 DAT

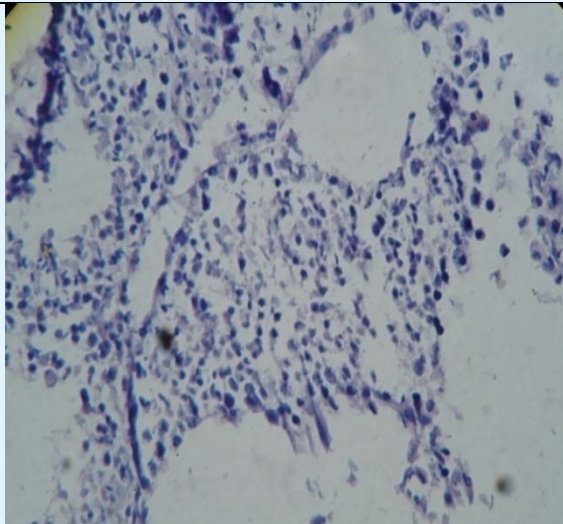


Figure 2: Degradation of seminiferous tubule, scattering of spermatogonia seen.

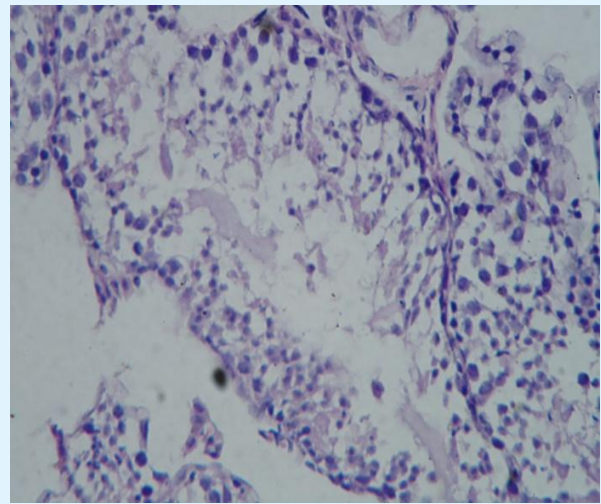


Figure 3: No. of sperms has decreased in seminiferous tubule. Wall of seminiferous tubule is also degraded.

Discussion

The degradation of seminiferous tubules, scattering of spermatogonia were observed. The number of sperms decreases in seminiferous tubules. The degradation of wall of seminiferous tubules was also observed.

The adverse effects of endosulfan on seminiferous tubules are similar to earlier reports [1,11-13]. This may be due to degradation of sertoli cells which are principal structural element of the seminiferous epithelium and provide physical support and an environment conducive to germ cell development and maturation [14].

Conclusion

Endosulfan is important pesticide exclusively used around the globe. It can cause behavioural changes as well as testicular toxicity in mammals. The judicious use of Endosulfan is highly recommended.

Reference

1. Choudhary N, Joshi SC (2003) Reproductive toxicity of Endosulfan in male albino rats. Bull Environ Contam Toxicol 70(2): 285-289.

2. Lopez-Carrillo L, Torres-Arreola L, Torres-Sanchez L, Espinosa-Torres F, Jiménez C, et al. (1996) Is DDT use a public health problem in Mexico?. *Environmental Health Perspectives* 104(6): 584-588.
3. Rivero-Rodriguez L, Borja-Aburto VH, Santos-Burgoa C, Waliszewskiy S, Rios C, et al. (1997) Exposure assessment for workers applying DDT to control malaria in Veracruz, Mexico. *Environmental Health Perspectives* 105(1): 98-101.
4. Aulakh RS, Bedi JS, Gill JPS, Joia BS, Pooni PA, et al. (2007) Occurrence of DDT and HCH insecticide residues in human biopsy adipose tissues in Punjab, India. *Bulletin of Environmental Contamination and Toxicology* 78(5): 330-334.
5. Ranjit K, Ali MD, Singh JK, Nath A, Kumar A (2013) Bioremedial effect of *Withania somnifera* on ultrastructure of certoli cells of endosulfan exposed mice. *European Journal of Toxicological Sciences* 1(1): 24-34.
6. Dyer O (1995) Decline in male fertility may be linked to insecticide. *British Medical Journal* 311(6996): 11-12.
7. Daxenberger A (2002) Pollutants with androgen-disrupting potency. *European Journal of Lipid Science and Technology* 104(2): 124-130.
8. Albanis TA, Hela D, Papakostas G, and Goutner V (1996) Concentration and bioaccumulation of organochlorine pesticide residues in herons and their prey in wetlands of Thermaikos Gulf, Macedonia, Greece. *Science of the Total Environment* 182(1-3): 11-19.
9. Feist GW, Webb MAH, Gundersen DT, Foster EP, Schreck CB, et al. (2005) Evidence of detrimental effects of environmental contaminants on growth and reproductive physiology of white sturgeon in impounded areas of the Columbia River. *Environmental Health Perspectives* 113(12): 1675-1682.
10. Lopez-Espinosa MJ, Lopez-Navarrete E, Rivas A, Fernandez MF, Nogueras M, et al. (2008) Organochlorine pesticide exposure in children living in southern Spain. *Environmental Research* 106(1): 1-6.
11. Chitra KC, Latchoumycandane C, Mathur PP (1999) Chronic effect of endosulfan on the testicular functions of rat. *Asian J Androl* 1(4): 203-206.
12. Sinha N, Narayan R, Shanker R, Saxena DK (1995) Endosulfan induced biochemical change in testes of rats. *Vet Hum Toxicol* 37: 547-549.
13. Wango EO, Onyango DW, Odongo H, Okindo E, Mugrweru J (1997) In vitro production of testosterone and plasma levels of leuteinising hormone, Testosterone and Cortisol in male rats treated with Hepatachlor. *Pharmacol Toxicol Endocrinol* 118(3): 381-386.
14. Tindall DJ, Rowley DR, Murthy L, Lipshultz LI, Chang CH (1985) Structure and biochemistry of the Sertoli cell. *Int Rev Cytol* 94: 127-149.