

Management of Toxic Goitre

Bhaskar G* and Sujit KB

Glocal Hospital, Krishnanagore, West Bengal, India

***Corresponding author:** Bhaskar Ghoshal, Glocal Hospital, Krishnanagore, West Bengal, India, Tel: + 91-9433054857; E-mail: drbhaskar_ghosal@rediffmail.com

Image Article

Volume 2 Issue 1

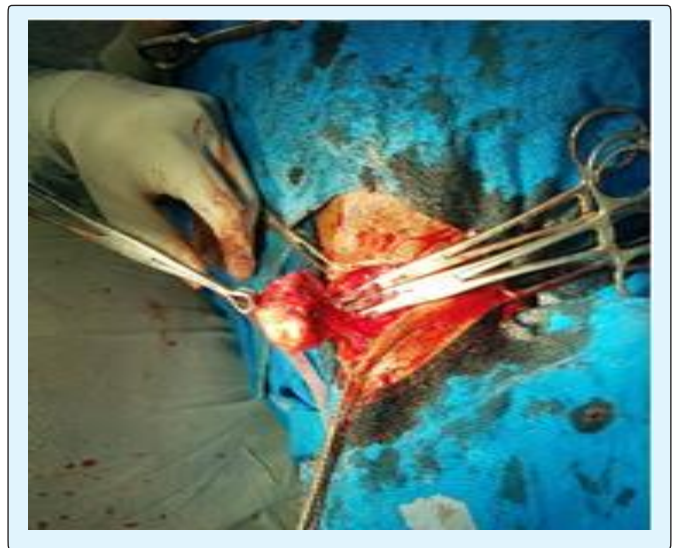
Received Date: March 03, 2017

Published Date: April 03, 2017

DOI: 10.23880/vvoa-16000107

Two cases of exophthalmic goiters (Figure) presented to the outpatient's department of Glocal Hospital, Krishnanagore, West Bengal, India, who were admitted to the hospital and detailed work up was made before operative intervention was made. Noteworthy to mention that the patients had taken Carbimazole for 2 to 5 years. Surgery involved sub-total thyroidectomy in Grave's disease. These presentations are rare. Wide excision of the toxic nodule was performed in the case which revealed a toxic nodule. Distinct improvement in the exophthalmos in the case of Grave's disease resulted following surgery.

Exophthalmas



Exophthalmas



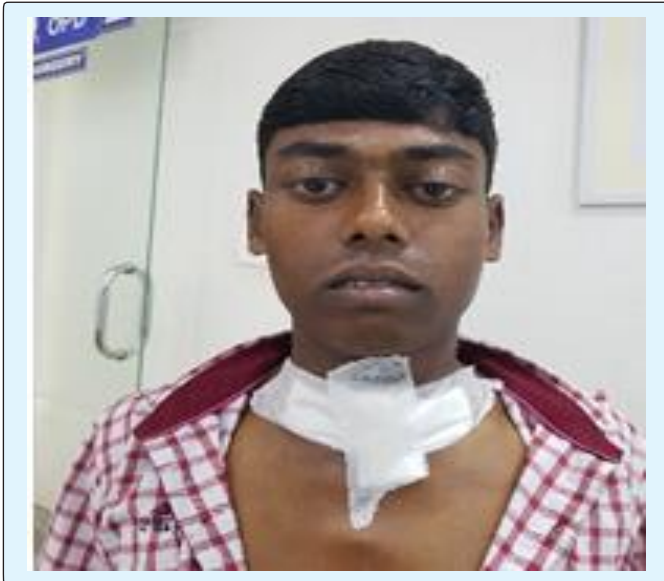
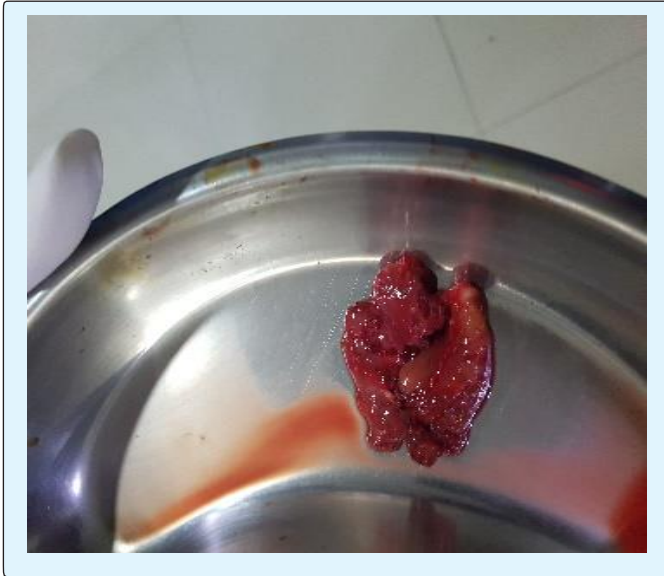
Figure: Two cases of exophthalmos.