

New Technologies and Reconstructive Surgery Cancer of the Vulva

Cherenkov VG*

Novgorod University, Russia

*Corresponding author: Cherenkov VG, Jaroslav The Wise Novgorod University, Veliky Novgorod, Russia, Email: v.g.cherenkov@yandex.ru

Research Article

Volume 3 Issue 2

Received Date: May 20, 2019

Published Date: July 12, 2019

DOI: 10.23880/whsj-16000130

Abstract

With vulvar dysplasia, sclerotic deprive and suspected cancer under our observation there were 92 patients. The effectiveness of treatment of vulvar dystrophy (VIN I-II degree) by the method of photodynamic therapy (PDT) 45.8±4.7%. However, dysplasia II - III degree, sclerotic changes with the formation of pronounced horn scales prevents the full PDT and recurrence of the disease. Therefore, the treatment of choice is surgical treatment with a reconstructive plastic. The use of new reconstructive plastic surgery, including with the use of abdominal skin and fascial flap combined with vascularized lower segments of the rectus muscles (patent for invention № 2580665 from 11.11.14), have helped to reduce complications, improve cosmetic effect and reduce the duration of lymphorrhoea in 2-3 days.

Keywords: Vulvar cancer; PDT; Cryoapplication; Reconstructive plastic surgery of the abdominal skin and fascial and lower segments of the rectus muscles

Introduction

Until recently, the main etiological factors of cancer of the vulva related disturbances in the neuroendocrine homeostasis. In the modern system of pathogenesis special attention is given papilloma infection (HPV). Latest play a leading role in the Genesis of not only cervical cancer but also that offers a new way to look at this problem [1,2]. Currently, PB is increasingly diagnosed in reproductive age, which in some way is connected with increasing frequency HPV of infection and incidence of vulvar intraepithelial neoplasia (VIN) among young women.

In 1993, the International society for the study of diseases of the vulva and vagina and the International society of gynaecological pathology adopted a new

classification of diseases of the vulva, which is based on pathological changes:

I. Benign lesions of the vulva

- Sclerotic zoster.
- Squamous cell hyperplasia.
- Other dermatoses.

II. Vulvar intraepithelial neoplasia (VIN)

- Squamous vulvar intraepithelial neoplasia.
 - VIN 1 - corresponds to mild dysplasia of the vulva.
 - VIN 2 - corresponds to moderate dysplasia of vulva.
 - VIN 3 - corresponds to severe dysplasia of the vulva and Ca in situ.
- Malosolenoj vulvar intraepithelial neoplasia
 - Paget's Disease.
 - Melanoma in situ.

III. Invasive cancer

Often one of the patients can observe the different pathological States that must be considered and classified.

Able to treat precancerous processes and prevent the development of cancer is difficult, but the real problem of modern gynecology [3,4]. Some authors the solution to this problem is associated with the development of methods for cryosurgery, and photodynamic diagnosis and photodynamic therapy [5]. Others believe that the organ-saving treatment of patients with neurodystrophic process, with a vulvar intraepithelial neoplasia and early cancer leads to relapse, and therefore in need of radical treatment [6].

However, to date not solved the methodological aspects of detection and treatment of vulvar dysplasias and early cancers of the vulva. In works on RV [7,8] indicate the importance of magnifying diagnosis and morphological methods. At the same time, stated that "the information content of the smears low" (up to 57% for summary data). "Often smears find only Horny scales and elements of inflammation, introducing the doctor astray."

Objective

Comprehensive assessment and improvement of methods of diagnostics and treatment of vulvar dysplasias and early cancers.

Material and Methods

With vulvar dysplasia, sclerotic deprive and suspected cancer in regional oncologic dispensary from 2012 directed 92 of the patient.

The examination we carried out with the use of colposcope (15 fold increase), allowing a high degree of confidence to select sites for target biopsy. Given the multicentric growth, as a rule, morphological study of vulvar dystrophies started with obtaining cytological material (smears and scrapings) from the suspicious areas (Figure 1).

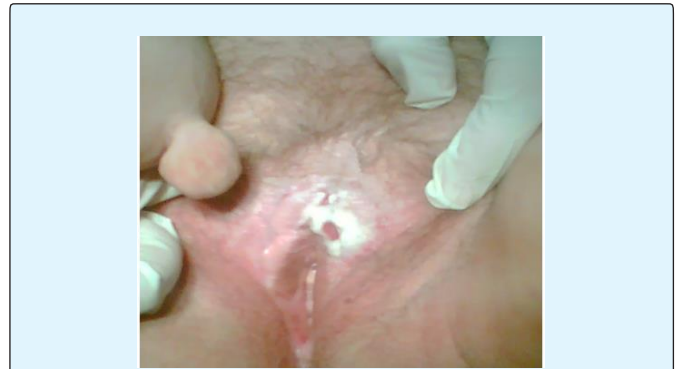

Figure 1: Patient K, 76 years old. D-z: Cancer of the vulva (T1NoMo) in the area of the clitoris on the background of sclerotic lichen. Soft fibroma of the skin of the inner thigh.

In the literature available to us we have not found a description of the method of collection of material for cytological examination vulvar dysplasias as it is used for cytological screening of cervical cancer. Given that development of foci of RV occurs on the background of sclerotic zoster and increased keratinization of epithelial tissue, we used the technique of scraping with a scalpel consisting of two steps: 1) removing (scraping) keratinized scales of the epithelium of the 4-5 most suspicious areas; 2) scarification and receiving cells from deeper layers within the basal layer before the "dewdrops" of blood.

Results

The results of cytological studies, we used incisional biopsy with a scalpel under local infiltration anesthesia (0.5% p-p of novocaine or lidocaine). And only when expressed scopinich and saucer-like forms of cancer a biopsy was performed by conchotomy. As can be seen from (Table 1), the cytological examination in 79 of the 92 patients with aimed vulvar dysplasia allowed at $76.0 \pm 3.4\%$ of cases to establish a correct diagnosis, including 13 cases against this background, the cancer (stage 0-1), which is significantly higher than according to the literature - 57%.

N	Morphological variant of pathology of the vulva	The Number of patients	Cytology allowed	Appeared	
				Not informative	ncorrec
1	Vulvar intraepithelial neoplasia VIN and/or sclerotic zoster	79	59	19	1
2	basal cell carcinoma	1	1	-	-
3	Squamous cell carcinoma	12	10	-	2
	Just	92	70 (76, 0%)	19 (20, 6%)	3(3, 2%)

Table 1: Results of cytological studies of scrapings of the vulva.

And only 20, 6 ± 1 , 5% were not informative. Have a $3.2 \pm 0.6\%$ conclusion of catalogue was wrong. The sensitivity of Cytology in detecting different types of pathology NGOs amounted to 81.3 ± 3.9 and ranged from 76% in vulvar intraepithelial neoplasia (VIN) to 97% at the pre - invasive forms of cancer.

PDT we performed in 24 patients with diffuse vulvar dysplasia (VIN II-III) and PB to prepare the surrounding tissues, including 2 patients at relapse RV. As shown in Figure 2, dysplasia and sclerotic zoster transferred to the skin of the thigh, which cannot be used for forming skin-fascial flap without PDT. In their study, we used a second generation sensitizer – fotoditazin. Session of PDT was performed using 1.5-2 hours after intravenous drip infusion of the drug (LLC "Veta-Grand"), on average, 1.0 mg/kg of body weight in 100 ml of 0.9% solution of sodium chloride in terms of polystannanes of the room. Laser irradiation with a semiconductor device "Atcus-2" at the energy density of 80-250 j/cm² of laser power output 1 W and the exposure time from 10 to 30 minutes depending on the area affected areas by scanning. Method involves generation of atomic (singlet) oxygen, leading to death of the atypical cells. After 1.5-3 months came healing and tissue repair without deformities in 9 women with barely visible scarring. Patients followed from 1 year to 3 years. Five women with repeated photodynamic therapy, however, complete cure has managed to achieve only two. Thus, the PDT allowed curing vulvar dysplasia, only 11 of the 24 patients with I-II degree ($45.8 \pm 4.7\%$). The renewal of the skin itch and residual lesions leukoplakia was observed in 13 women, due to the insufficient exposure of laser exposure on each zone, especially when there are significant Horny scales.

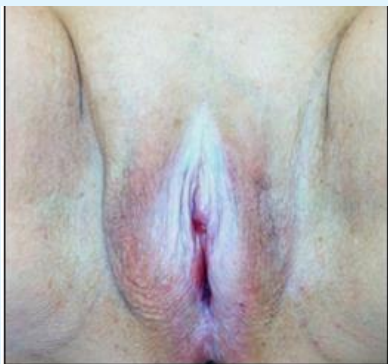

Figure 2: Carcinoma in situ on the background of diffuse sclerotic zoster, and vulvar dysplasia, passing on the skin of the thigh (Patient C 62 years).

Besides, PDT by moving the laser beam by hand does not allow avoiding subjectivity, and thus relapse. In such situations, in our opinion, requires an individual approach and combined treatment. As noted by the women they after PDT was only a temporary subjective effect, after which the itching resumed and they resorted to various folk remedies.

As noted by the women themselves after PDT was only a temporary subjective effect, after which the itching resumed and they resorted to various folk remedies.

For cancer of the vulva in order to avoid dispersion of tumor cells excision is always carried out radiowave scalpel and apparatus "Harmonics" In recent years, the excision of the tumor was preceded by her credibilitate to t - 185° using the apparatus ERBE, exposure 3-5 min (Figure 3). The results indicate the prospects of this approach, allowing a fixed tumor, it is more convenient to tighten and excise, to reduce blood loss.

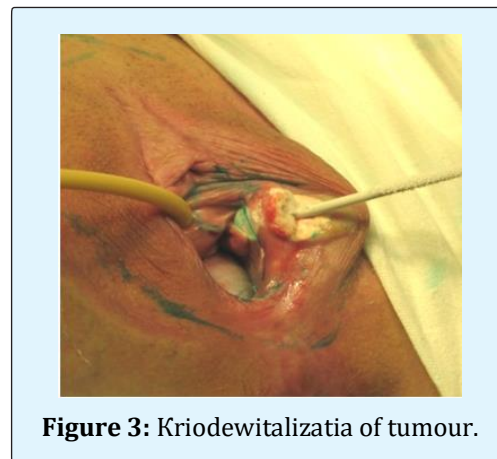


Figure 3: Kriodewitalizatia of tumour.

To improve quality, the formation of the amount of the external genitalia and reduce the lymphorrhea in recent times we have developed a method rekonstruktivnoi erasers (Patent No. 2580665 for invention dated 11.11.14) of the external genitalia through the mobilization of abdominal skin and fascial flap and the lower segments of the rectus muscles along with epigastrica inferior (Figure 4 a-d).

Closure of the wound was carried out at the beginning cross mobilized segments of direct muscles of a stomach on the vascular pedicle. Last create the missing volume of the labia majora and represent a unique plastic material for vascularization and lymph drainage. In the region of the decussation of the muscles and the ends of the

segment performed the fixation to the muscles of the vagina with absorbable sutures so that they hung over the mouth of the urethra and did not close the symphysis of the pubic bones.

The next step was sutured fascia rectus muscles of the abdominal wall. Then put 6-7 stitches by Donati on the skin of the perineum and posterior vaginal wall tension in order to determine to what level will the skin defect to be filled abdominal skin and fascial flap with no tension.

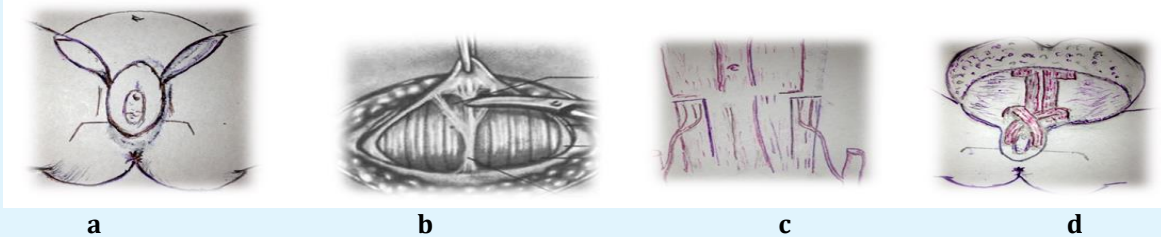


Figure 4: a) excision of the vulva and inguinal areas; b) and c) slit with a Pfannenstiel exposure of the rectus muscles and inferior epigastric; d) formation of the labia majora using cross-segments of the rectus muscles.

Abdominal skin and fascial flap was laid on the wound surface, adapting it by cutting off the excess and sharp areas of the skin, stitches. Determining the projection of the abdominal flap, adjacent to the pubis, imposes two provisory internal anchor sutures to the periosteum, which is then stitched to the abdominal flap (without the skin), forming the genital fold.

Then through a separate puncture of the abdominal flap in the inguinal areas has introduced an active drainage in the inguinal-femoral area. Then every 0.7-0.8 cm for the tightness of stitches on the skin and the vaginal mucosa around the entire circumference and nodal skin sutures for Donati in inguinal-femoral area.

Surgery was performed in 14 women, mostly aged 45 to 55 years with abdominal obesity. The process is

localized on the skin and mucosa of the anterior half of the vulva. In one case, focal leukoplakia was as an independent disease, in the other case was diagnosed with the initial cancer. Healing was by primary intention, with the exception of 1 woman (8, 3±1, 4%) with obesity and diabetes type II. An important aspect of reconstructive vulvectomy abdominal flap combined with segments of straight muscle on the vascular pedicle has been the reduction in the duration of lymphorrhea in 2-3 days, and the formation of the appearance of the organ.

Discussion

The use of cryoapplication and individual approach of wound closure, including abdominal flap according to the technique allowed reducing mortality with a tendency to increase morbidity.

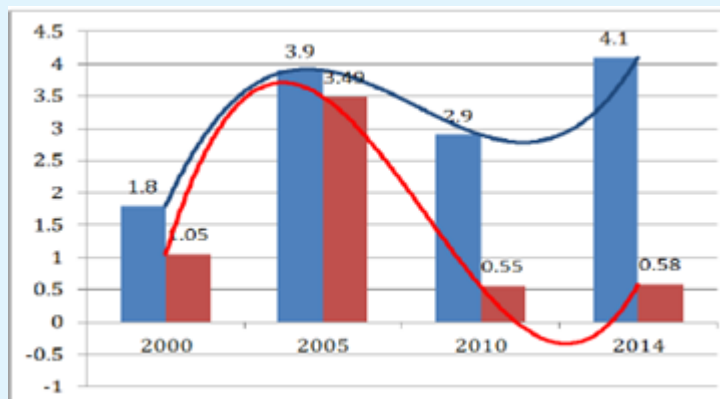


Figure 5: Morbidity and mortality from RV (100 000 wives.us.) in Novgorod region.

Conclusions

- The treatment of choice for vulvar dystrophy (VIN I-II degree) is PDT, which is in the diffuse forms the transition to the skin back of the thigh and with strong Horny scales should be used in combination with reconstructive plastic.
- The use of reconstructive plastic surgery, including use of vascularized lower segment of the rectus abdominis muscle is an individual method of choice in young women with cancer of the vulva and vulvar dystrophies (VIN II-III), a way of preventing the development of invasive forms of cancer, helps to reduce.

References

1. Ashrafyan LA, Kharchenko N (2006) In: Kiselev VI vulvar Cancer: etiopathogenic concept. Moscow: 192.
2. Gubaidulina TN, Zharov VA, Chernova LF (2008) Efficiency of surgical treatment of patients with background processes precancer and early cancer of the vulva with the use of reconstructive plastic surgery. Surgery (2): 48.
3. Zharov AV, Vazhenin AV (2005) Optimization of the treatment of patients with cancer of the vulva.-Chelyabinsk: 131.
4. Buscema J, Naghashfar Z, Sawada E, Daniel R, et al. (1988) The Predominance of human papillomavirus type 16 in vulvar neoplasia. Obstet Gynecol 71(4): 601-606.
5. Krikunova LI, Kaplan MA, Rykova EV (1999) The Role of photodynamic therapy in the treatment of vulvar cancer. International conference Obninsk 32-33.
6. Urmancheyeva AF (2006) Epidemiology of cancer of the vulva. Risk factors and prognosis. Practical Oncology 7(4): 189-196.
7. Chulkova OV, Novikova EG, Sokolov VV, Chulkov EA (2006) Diagnosis and treatment of background and precancerous diseases of the vulva. Practical Oncology. Tumor of the vulva and vagina 7(4): 197-204.
8. Knapstein PG (1985) Advanced treatment of vulvar cancer by plastic reconstructive procedures. In: Knapstein PG, M Mahlke, W Poleska, W Zeuner. Zbl Gynecol 107(24): 1479-1487.

